



Available online at www.sciencedirect.com

ScienceDirect

Journal homepage: www.elsevier.com/locate/cortex



Special issue: Research report

Visual imagery influences brain responses to visual stimulation in bilateral cortical blindness

Beatrice de Gelder ^{a,b,c,*}, Marco Tamietto ^{b,d}, Alan J. Pegna ^{e,f} and Jan Van den Stock ^{a,g,1}

^a Brain and Emotion Laboratory Leuven (BELL), Division of Psychiatry, Department of Neurosciences, KU Leuven, Leuven, Belgium

^b Cognitive and Affective Neuroscience Laboratory and CoRPS – Center of Research on Psychology in Somatic Diseases – Tilburg University, Tilburg, The Netherlands

^c Cognitive Neuroscience, Faculty of Psychology and Neuroscience, Maastricht University, Maastricht, The Netherlands

^d Department of Psychology, University of Torino, Torino, Italy

^e Laboratory of Experimental Neuropsychology, Neurology Department, Geneva University Hospitals, Genève, Switzerland

^f Faculty of Psychology and Educational Science, University of Geneva, Geneva, Switzerland

^g Old Age Psychiatry, University Hospitals Leuven, Leuven, Belgium

ARTICLE INFO

Article history:

Received 30 May 2014

Reviewed 19 July 2014

Revised 29 August 2014

Accepted 18 November 2014

Published online xxx

Keywords:

Mental imagery

Face perception

Cortical blindness

Emotion perception

Visual cortex

ABSTRACT

Mental imagery is a powerful mechanism that may facilitate visual perception as well as compensate for it. The role of V1 in mental imagery is still a matter of debate. Our goal here was to investigate whether visual imagery was still possible in case of bilateral V1 destruction behaviorally evidenced by total clinical blindness and if so, whether it might boost residual visual perception. In a factorial fMRI design, faces, scenes or scrambled images were presented while a rare patient with cortical blindness over the whole visual field due to bilateral V1-lesions (TN) was instructed to imagine either an angry person or a neutral object (tree). The results show that visual imagery of a person activates frontal, parietal and occipital brain regions similar to control subjects and hence suggest that V1 is not necessary for visual imagery. In addition, the combination of visual stimulation and visual imagery of socio-emotional stimuli triggers activation in superior parietal lobule (SPL) and ventromedial (vmPFC) and dorsolateral prefrontal cortex (DLPFC). Finally, activation during residual vision, visual imagery and their interaction overlapped in the SPL, arguing for a central role of feeling in V1-independent vision and imagery.

© 2014 Elsevier Ltd. All rights reserved.

* Corresponding author. Cognitive Neuroscience, Maastricht University Maastricht, Oxfordlaan 55, 6229 ER Maastricht (NL), The Netherlands.

E-mail address: b.degelder@maastrichtuniversity.nl (B. de Gelder).

¹ B.d.G. and J.V.d.S. contributed equally to this work.

<http://dx.doi.org/10.1016/j.cortex.2014.11.009>

0010-9452/© 2014 Elsevier Ltd. All rights reserved.

1. Introduction

Visual imagery is a powerful mental mechanism and has been a research topic since the beginning of psychological science (James, 1890). Earlier, philosophers have argued that imagination involves the same processes as perception, albeit with lower intensity (Bain, 1855). However, as imagination is an intrinsically subjective phenomenon, there are little measures available today that allow its objective quantification. Psychometric instruments have been developed to quantify visual imagery, although they primarily assess some form of intensity of subjective experiences (Pearson, Deeprose, Wallace-Hadrill, Burnett Heyes, & Holmes, 2013). Currently, functional neuro-imaging is considered an important tool to investigate imagination and the results have partly supported the early claims, namely that visual perception and imagination of a particular stimulus activate the same areas in V1. This has led to the hypothesis that V1 is necessary for visual imagery (Kosslyn et al., 1993; Le Bihan et al., 1993). The critical test for this hypothesis requires patients with destruction of V1, as they offer a unique opportunity to clarify the neuro-functional basis of visual imagery and the postulated necessary role of V1. There have been several imagery reports about patients with unilateral or bilateral V1-damage. For example, patient SBR shows bilateral damage and hypo-perfusion in the calcarine sulcus, yet imagery of particular stimulus categories like faces and houses activate the corresponding category-specific areas in the ventral stream (Bridge, Harrold, Holmes, Stokes, & Kennard, 2012; Bridge et al., 2010). This has been taken as counter-evidence for the postulated necessity of V1 for visual imagery. However, standard perimetry testing in this patient revealed incomplete visual field defects and moreover, he was able to detect high contrast Gabor patches throughout the visual field, questioning the extent and degree of his blindness. Partial visual field deficits do not fully support solid conclusions about the necessity of V1 for visual imagery as the contribution of the intact part of the visual field cannot be excluded. To our knowledge, only one imagery study was conducted on a patient with total bilateral V1-damage. The observation that he was able to draw objects was interpreted as reflecting intact imagery, hence evidencing the unnecessary role of V1 (Zago et al., 2010). However, this patient also showed Anton's syndrome, which is the denial of his blindness and is often associated with confabulations. Furthermore, no functional imaging data were reported. Thus, it is unclear whether and to what extent these findings can be informative about the relations between visual cortex and mental imagery and could be extended to other cases of complete cortical blindness in the absence of other concomitant neuropsychiatric symptoms. Support for the necessity of V1 for visual imagery was reported in a study with a patient with hypo-metabolism in the occipital cortex and also impaired visual imagery (Policardi et al., 1996). However, the lesion of this patient extended to the temporal cortex, which may contribute to the imagery deficit. With all these reservations in mind, a dominant current view is that V1 is not necessary for visual imagery, but imagery deficits may occur when the (structural and/or functional) damage extends to other areas (Bartolomeo, Bourgeois, Bourlon, & Migliaccio,

2013). However, the most solid evidence for the epiphenomenal role of V1 in visual imagery would come from an objective measure of preserved visual imagery function in a patient with totally a-functional V1 as behaviorally evidenced by complete clinical blindness. The results we present here from a patient (TN) with bilateral occipital lesions due to stroke may provide the best fit to the criteria reported so far.

Secondly, we were able to investigate imagery–perception interactions in this patient without the interference of conscious perception (Rode, Revol, Rossetti, Boisson, & Bartolomeo, 2007). There is accumulating evidence that cortically blind patients are able to process stimulus features like affective or social valence in the absence of conscious awareness of the stimuli (Buetti et al., 2013; Burra et al., 2013; de Gelder et al., 2008; Pegna, Khateb, Lazeyras, & Seghier, 2005; Pegna, Landis, & Khateb, 2008; Tamietto & de Gelder, 2010; Van den Stock, Tamietto, Hervais-Adelman, Pegna, & de Gelder, in press; Van den Stock et al., 2011; Van den Stock, Tamietto, Zhan, et al., 2014). We presented patient TN, the only available case in the literature with bilateral cortical blindness and “blindsight” (i.e., the ability to process stimulus features in the absence of conscious awareness), with intact and scrambled affective faces and scenes that were shown simultaneously with specific visual imagery instructions.

Based on the double dissociations that have been reported for visual imagery on the one hand and visual perception on the other hand at higher order levels of the visual processing stream like color and object categories (e.g., faces), in verbal material as well as in other modalities (Bartolomeo et al., 1998; Dulin et al., 2011; Guaita et al., 2009; Metcalfe, Langdon, & Coltheart, 2010) we hypothesize intact imagery activation in higher order cortical regions (Mousikou, Coltheart, Finkbeiner, & Saunders, 2010).

2. Materials and methods

2.1. Participants

2.1.1. Case TN

TN is a 59-year-old right-handed male physician who suffered two consecutive occipital strokes at age 52, destroying the bilateral striate cortices. In summary, the lesion includes nearly the complete primary visual cortices in both hemispheres. There is some residual tissue visible on the ventral anterior calcarine sulcus, which appears completely deafferented on MRI (for a detailed MRI display, see Van den Stock, Tamietto, Zhan, et al., 2014). Furthermore, multimodal magneto- as well as electro-diagnostic investigations did not reveal any evidence for residual functioning of V1. Extensive visual perimetry testing with multiple stimulus conditions at the time of the present study confirmed blindness over the whole visual field, consistent with the case history (Van den Stock, Tamietto, Zhan, et al., 2014). Despite blindness over the whole visual field, residual vision has been documented in TN for several features, including navigation (de Gelder et al., 2008), categorization of body stimuli (Van den Stock, Tamietto, Hervais-Adelman, et al., in press; Van den Stock, Tamietto, Zhan, et al., 2014) and facial affect recognition (Pegna et al., 2005). Furthermore, on the basis of a localizer scan,

comparison of visual stimuli with baseline as well as comparison of objects with scrambles at the liberal threshold of $p < .1$ revealed no activations in striate cortex (Van den Stock, Tamietto, Zhan, et al., 2014).

2.1.2. Controls

To compare the results of TN with normative data, we included 2 male control participants (30 and 43 years old) who performed 2 runs with a similar task (see below) with their eyes closed.

2.2. Stimuli and design

To have a balanced design adapted to this specific situation, a stimulus always consisted of an imagery task combined with a visual stimulation.

2.2.1. Visual stimuli

The visual stimulus was either a real stimulus (a face or a scene) or a fully scrambled image always filling the complete screen and serving as control. For the face materials four male identities of the Karolinska Directed Emotional Faces set (Lundqvist, Flykt, & Öhman, 1998) displaying an angry expression in frontal view with gaze directed at the viewer (Burra et al., 2013) were selected. They were used to construct four visual face stimuli consisting of simultaneous presentation of the same face in each of the four visual quadrants (see Fig. 1). This was done in order to fill the screen and have the

face visible independently of where TN was fixating and to make the visual face condition similar to the visual scene condition. Four landscape images depicting natural disaster scenes (e.g., collapsed buildings) were downloaded from the internet and selected for evenly distribution of visual information. The eight visual stimuli (4 faces, 4 scenes) were then scrambled by dividing each into 100×100 squares and then randomly rearranging the squares.

2.2.2. Auditory stimuli

The imagery variable was manipulated through the task, which was either to imagine an angry person or to imagine a tree viewed from a distance. The latter was chosen because it is a frequently encountered neutral object and, at appropriate distance, has a comparable overall shape to a person. Furthermore, both conditions differ both in semantic category as in emotional valence. We reasoned that this might constitute a powerful imagery contrast. We did not choose to compare imagery of an emotional with a neutral stimulus of the same category, as the visual similarity between both conditions might result in a false negative result, i.e., no differential activations despite intact imagery. Verbal auditory instructions regarding imagery were presented to TN through the scanner intercom system. At the transition from stimulation to fixation blocks (see 2.2.3) TN was instructed to imagine 'total darkness'. Before the scanning session, instructions were reviewed with TN and a practice imagery session was performed outside the scanner.

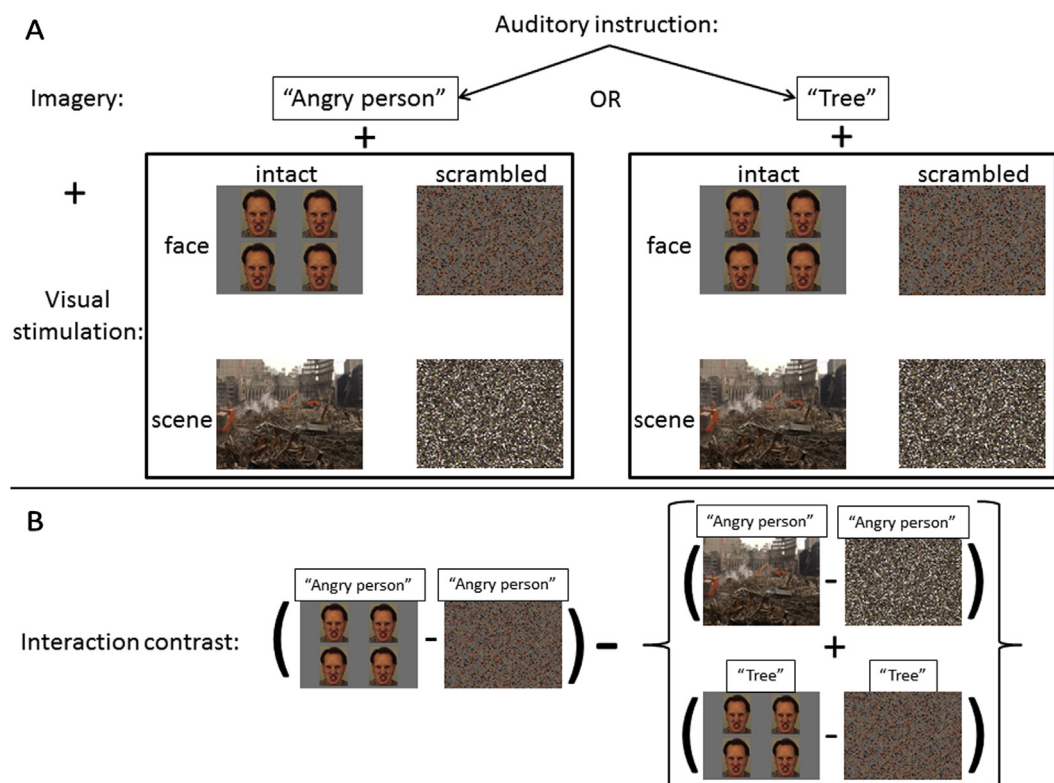


Fig. 1 – A): Schematic overview of the design. Blocks with visual stimulation were always accompanied by an imagery task and alternated with fixation blocks, during which TN was instructed to imagine 'total darkness'. Imagery instructions were auditory delivered by an experimenter and consisted of "angry person" and "tree" imagery instructions. Visual stimulation consisted of a 2 category (face vs scene) \times 2 modality (intact vs scrambled) factorial-blocked design. B) Schematic presentation of the interaction contrast.

2.2.3. Procedure

The fMRI-scanning session consisted of three functional runs, during which fixation blocks alternated with stimulation blocks. The functional runs were followed by a structural scan. In all conditions TN was shown a visual stimulus while performing one of the two imagery tasks. We did not include an imagery condition without visual stimulation but replaced that with a scrambled visual stimulation condition, as this controls for low-level visual properties like luminance, which may be particularly relevant for the case of TN. During fixation blocks, TN was instructed to imagine total darkness, as an exogenous control of the imagery processing occurring during fixation blocks. We considered this to be a better control than to instruct TN to 'image nothing', which constitutes a pragmatic paradox. TN was instructed to keep his eyes open and look straight ahead.

The experiment consisted of a 2 (imagery: angry person or tree) \times 2 (visual category: faces or scenes) \times 2 (visual modality: intact or scrambled images) factorial-blocked design. Stimulation blocks lasted 18 sec during which 4 stimuli were randomly presented via a projection screen on a mirror attached to the head coil for 4,250 msec with a 333 msec interstimulus interval. Fixation blocks consisted of projection of a grey screen and lasted 11,250 msec. One functional run consisted of 24 pseudo-randomized stimulation blocks, 3 of every condition, adding up to a duration of 11.9 min. At the beginning of every stimulation block, TN was verbally instructed by an experimenter through the scanner intercom system to imagine either an angry person or a tree. Prior to scanning, TN was given a scenario to facilitate the imagery instructions. For the angry person imagery, TN was primed to imagine he was walking down the street and he was being approached by an angry person. For the tree imagery, TN was primed to imagine he was walking towards the bus station and came across an open plain with a tree at the center. At the end of the stimulation block, TN was instructed to imagine total darkness. See Fig. 1A for a schematic presentation of the design and stimulus examples.

2.2.4. MRI-scanning parameters

During the functional runs 317 T2* weighted volumes were acquired with 32 axial slices (slice thickness = 3 mm; .3 mm gap; in plane resolution = 1.7 \times 1.7 mm; matrix size = 128 \times 128; FOV = 220 mm) covering the whole brain (TE = 30; TR = 2250 msec). Slices were scanned in an interleaved ascending order. The parameters of the structural volume are described elsewhere (Van den Stock, Tamietto, Zhan et al., 2014).

2.2.5. fMRI preprocessing

The first 3 volumes of every functional run were discarded to allow for T1 equilibration. Preprocessing included slice scan time correction, 3D motion correction and temporal filtering. Functional data were then co-registered with the anatomical volume and transferred into Talairach space. The statistical analysis was based on the General Linear Model, with each condition defined as a predictor. The threshold was set at $p < .001$ (corrected for multiple comparisons at cluster level following 1000 Monte Carlo simulations) (Forman et al., 1995).

3. Results

3.1. Overlap lesion-categorical areas

To evaluate whether TN's lesion included category selective regions LOC and fusiform face area (FFA), we overlaid a probabilistic atlas of LOC and FFA (Frost & Goebel, 2012) on the cortical reconstruction of TN. The results are displayed in Fig. 2 and revealed that both the LOC and FFA with the lowest threshold fall nearly completely in the lesion. Only a small anterior portion of the FFA projects on TN's cortical reconstruction.

3.2. Subjective imagery

After the scanning session, we inquired about TN's subjective feelings concerning the imagery instructions and the visual

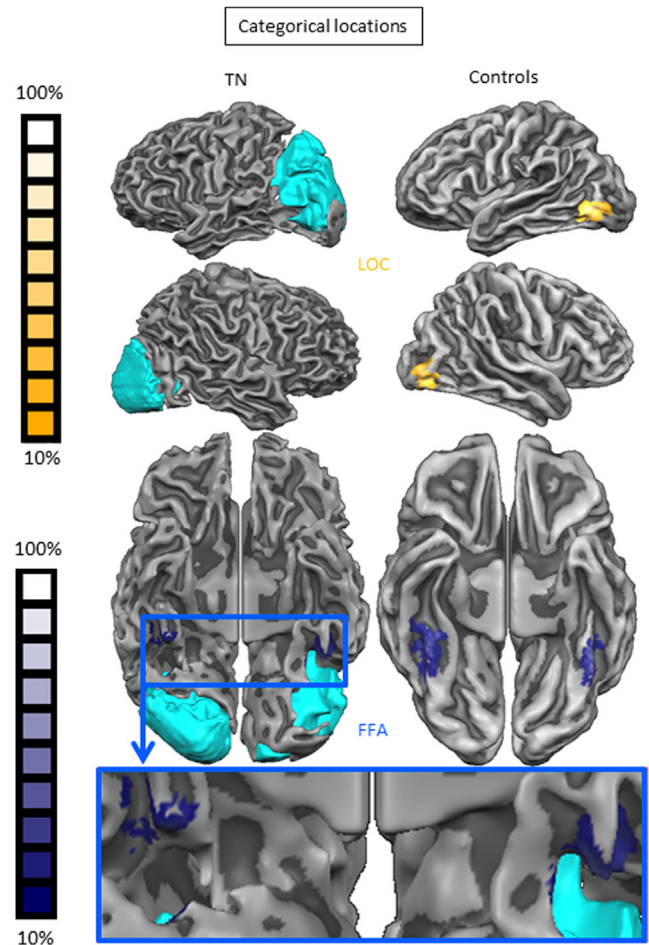


Fig. 2 – Projection of categorical areas right LOC and FFA on the cortical reconstruction of TN (left column). The right column shows the locations of LOC (lateral views in top rows) and FFA (ventral view in third row) on an average aligned cortical reconstruction of the subjects ($N = 10$) from which the probabilistic maps were constructed (Frost & Goebel, 2012). Color codings represent the percentage overlap across control subjects. The bottom illustration shows a zoomed view on TN's fusiform gyri and displays that nearly the entire FFA regions are lesioned.

stimulation. He reported that it was easy to follow the instruction and felt confident about his capacity to imagine appropriately what was requested. Furthermore, TN acknowledged that he based his imagery on personal experiences, i.e., he claimed that he imagined specific autobiographical events concerning a tree and an angry person encounter. Although this does not directly evidence the visual nature of TN's imagery, it is suggestive for the activation of visual memories, compatible with visual imagery processing. Concerning the visual stimulation he did not report any conscious visual perception of the images displayed on the screen.

3.3. Neural correlates of visual imagery

3.3.1. Whole brain analysis

We first explored the brain regions that were triggered during active imagery of a visual stimulus, as compared to imagery of total darkness. For this purpose, we performed a conjunction analysis of angry person versus total darkness imagery on the one hand, and tree versus total darkness imagery on the other hand. The left hemisphere activation consisted of 1 cluster covering fronto-parietal regions, while the right hemisphere activation also included a medial anterior occipital region partly overlapping the inferior part of the parieto-occipital sulcus (see Fig. 3A).

3.3.2. ROI-analysis

Furthermore, we combined the current data with the data we obtained in another study with TN. In that study, we presented (neutral) faces, (neutral) bodies, butterflies, cars and scrambles to TN. The ROI-analysis concerned all areas that responded either to faces (compared to butterflies, cars, and scrambles) or bodies (compared to butterflies, cars, and scrambles) and include extrastriate body area (EBA) (Downing, Jiang, Shuman, & Kanwisher, 2001), superior temporal sulcus (STS) (Haxby & Gobbini, 2011), amygdala (Van den Stock, Vandenbulcke, Sinke, Goebel, & de Gelder, 2014) and orbitofrontal cortex (OFC) (Van den Stock, Vandenbulcke, Sinke, & de Gelder, 2014). The results are presented in Table 1 and reveal that the majority of these regions (that have also been associated with body and/or face perception in normal subjects) including EBA, STS, OFC, amygdala and superior parietal lobule (SPL) respond more to the angry person imagery than to the darkness imagery.

3.3.3. Neural correlates of angry person imagery

We then explored the brain areas that were more active during imagery of an angry person than during imagery of a tree, regardless of the different visual conditions. This contrast showed activation in motor and somatosensory areas as well as in temporal and occipital areas bilaterally. At the subcortical level, the left cerebellar hemisphere was activated together

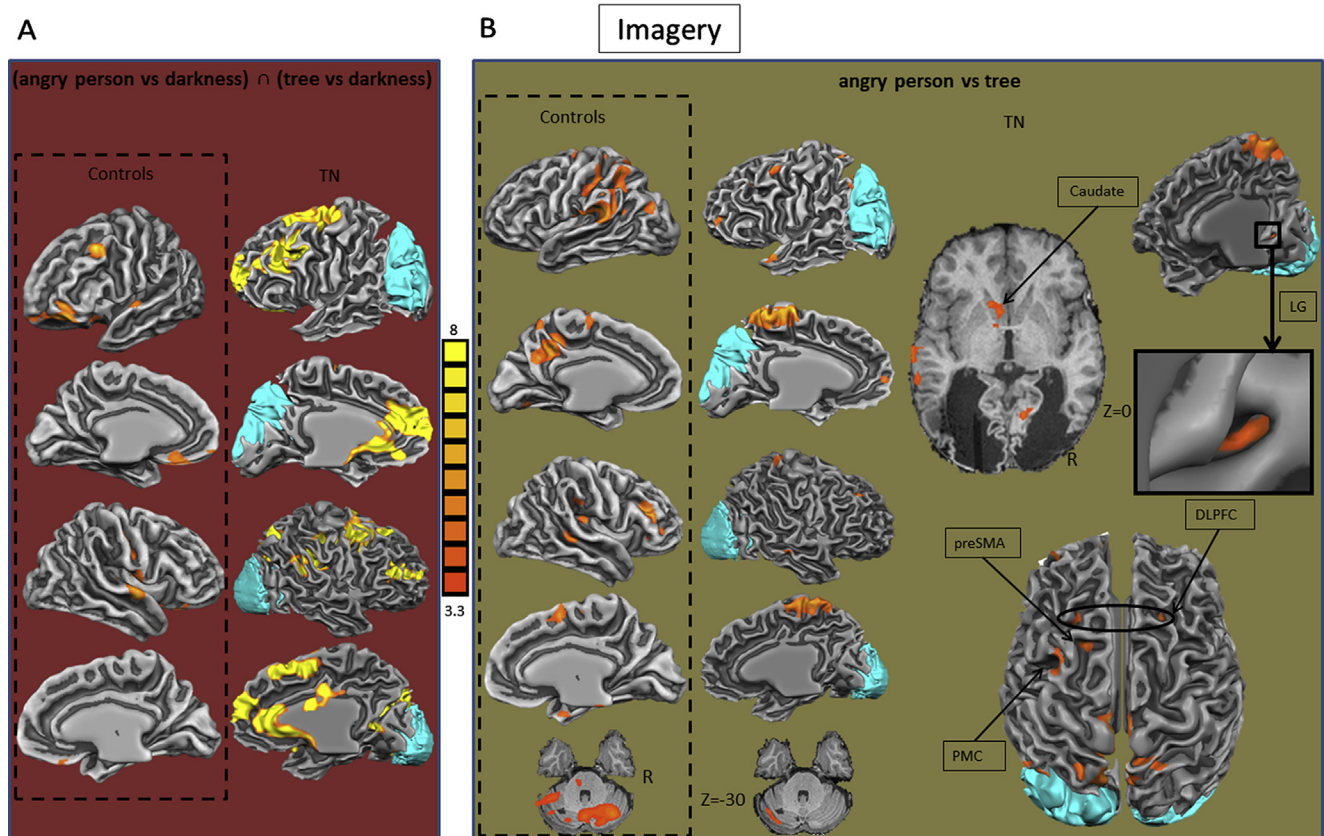


Fig. 3 – Imagery results. A) Statistical activation maps of conjunction analysis of angry person versus darkness imagery and tree versus darkness imagery for controls and TN. B) Statistical activation maps of imagining an angry person compared to imagining a tree for controls and TN. The lesion is displayed in cyan. Talairach coordinates are reported. Statistical color coding is presented in the center. preSMA = pre-supplementary motor area; PMC = premotor cortex; DLPFC = dorsolateral prefrontal cortex; LG = lingual gyrus.

Table 1 – fMRI-results. XYZ refer to Talairach coordinates. t = t-value of peak voxel. N = number of voxels BA = Brodmann area; OFC = orbitofrontal cortex; SPL = superior parietal lobule; STS = superior temporal sulcus; SMG = supramarginal gyrus; EBA = extrastriate body area; SFG = superior Frontal Gyrus; PFC = prefrontal cortex; PMC = premotor cortex; MFG = middle frontal gyrus; PFC = prefrontal cortex; ACC = anterior cingulate cortex; PMC = premotor cortex; MFG = middle frontal gyrus; preCG = precentral gyrus; postCG = postcentral gyrus; IPL = inferior parietal lobule; MTG = middle temporal gyrus; TP = temporal pole; LG = lingual gyrus; SFS = superior frontal sulcus; AG = angular gyrus; PLV-SC-LGN = pulvinar-superior colliculus-lateral geniculate nucleus. Imagery × stimulation interaction activations are based on the contrast: (angry person imagery/angry face stimulation – angry person imagery/scrambled face stimulation) – [(angry person imagery/scene stimulation-angry person imagery/scrambled scene stimulation) + (tree imagery/angry face stimulation – tree imagery/scrambled face stimulation)].

		X	Y	Z	t	p	N	BA
ROI-analysis: angry person versus darkness imagery								
Frontal								
OFC	R	8	34	–22	8.566	.0000001	393	11
Parietal								
SPL	L	–14	–59	51	6.853	.0000001	405	5
Temporal								
STS/SMG	R	35	–30	27	13.910	.0000001	2916	22/39/40
Occipito-temporal								
EBA	R	41	–70	–6	8.323723	.0000001	401	18
Subcortical								
Amygdala	L	–10	–5	–12	6.363	.0000001	338	
Whole brain analysis								
Angry person versus tree imagery								
Frontal								
SFG (PFC)/ACC	L	–37	55	12	5.416	.0000001	1417	10
SFG (PMC)								
	L	–7	10	60	4.306	.00001	330	6
	L	–19	22	48	5.387	.0000001	410	6
	R	23	28	42	4.618	.000004	406	6
MFG (PMC)	L	–34	28	45	4.777	.000002	2333	6
Fronto-parietal								
SFG/preCG/postCG	L/R	–4	–20	66	6.779	.0000001	17252	2/3/4/5
Parietal								
IPL	L	–43	–59	45	4.991	.000001	1415	7
Temporal								
MTG	R	59	–23	–9	4.252	.00002	325	20
STS	L	–64	–35	–3	4.812	.000002	422	21
TP	L	–52	10	–15	5.172	.0000001	420	38
Occipital								
LG (V3)	R	11	–59	3	4.799	.000002	314	19
Subcortical								
Cerebellum	L	–43	–59	–30	4.303	.00001	408	
Ventral striatum/caudate	L	–7	4	–3	5.052	.000001	547	
Angry faces versus scrambled faces								
Frontal								
MFG (PMC)	L	–25	28	42	4.590	.000005	670	8
SFS (PMC)	R	32	16	39	4.507	.000007	503	8
ACC								
	L	–4	55	9	5.370	.0000001	976	10
	R	8	46	15	4.899	.000001	147	10
Parietal								
Precuneus	L/R	–4	–62	30	4.310	.00001	1178	31
SPL	L	–14	–53	69	3.867	.0001	138	5
Temporal								
SMG	R	44	–56	18	4.189	.00003	234	19
Subcortical								
Cerebellum	L	–4	–62	–27	4.399	.00001	203	
Scenes versus scrambled scenes								
Frontal								
OFC	R	35	37	–9	4.689	.000003	231	47
Parietal								
postCG	R	56	–8	36	5.673	.0000001	1580	40
	R	17	–35	48	4.780	.000002	2397	3
SMG								
	R	41	–41	39	4.648	.000004	342	7
	R	35	–59	36	4.814	.000002	1486	19
AG								
	R	44	–59	24	4.901	.000001	580	19

Table 1 – (continued)

		X	Y	Z	t	p	N	BA
Occipital								
LG (V2)	R	3	–68	–9	5.203	.0000001	501	18
Subcortical								
PLV/SC/LGN	L	–22	–26	0	4.867	.000001	1090	
<i>Imagery × stimulation interaction</i>								
Frontal								
preCG	L	–7	–26	57	4.771	.000002	372	4
	R	2	–26	60	4.333	.00001	476	4
Parietal								
SPL	L	–13	–56	66	6,584	.0000001	1846	5
Precuneus	R	14	–53	39	4.403	.00001	476	31
Occipital								
LG (V3)	L/R	5	–59	0	4.645	.000004	468	19

with a cluster in the left basal ganglia comprising the ventral striatum and the head of the caudate nucleus (Fig. 3B, Table 1).

3.4. Neural correlates of visual stimulation

We then compared each visual category with their corresponding scrambles, regardless of imagery condition. The faces versus scrambled faces contrast shows frontal lobe activity in the middle frontal gyrus (MFG), superior frontal sulcus (SFS) and anterior cingulate cortex (ACC)/ventromedial prefrontal cortex (vmPFC), parietal activation in precuneus and SPL and temporal lobe activation in the supramarginal gyrus (SMG) of the temporo-parietal junction (TPJ).

The scenes versus scrambled scenes comparison showed activations in the right orbitofrontal (OFC) and lingual gyrus in addition to the right primary somatosensory cortex (SI, post-central gyrus), SMG, angular gyrus (AG) and left precuneus. At the subcortical level, a cluster containing the pulvinar (PLV) and the superior colliculus (SC) was activated (Fig. 4A, Table 1).

3.5. Neural interaction between social emotion perception and imagery

To investigate the interaction between (non-conscious) perception and mental imagery of social emotional stimuli, we compared the combination of perception and imagery, controlled for their isolated effects as well as their low-level visual and non-emotional control conditions. This resulted in the following contrast: (angry person imagery/angry face stimulation-angry person imagery/scrambled face stimulation) – [(angry person imagery/scene stimulation-angry person imagery/scrambled scene stimulation) + (tree imagery/angry face stimulation – tree imagery/scrambled face stimulation)]. See Fig. 1B for a schematic presentation of the interaction contrast. This revealed activation in the bilateral precentral gyrus, lingual gyrus and right precuneus (Fig. 4B, Table 1).

3.6. Conjunction analyses

Finally, we examined the pair-wise and triple common activations between angry person imagery, angry face visual stimulation and their interaction by performing conjunction analyses between all contrast combinations. This showed that an area in the left superior parietal region was commonly activated in all three contrasts (Fig. 5, Table 2).

4. Discussion

Our first aim was to find evidence for visual imagery in the case of complete absence of V1 function and second, to investigate whether mental imagery boosted residual visual neural processing in this patient.

4.1. Subjective visual imagery

We have first documented here that in addition to bilateral V1, both the bilateral LOC and FFA (as defined by a probabilistic atlas) are nearly completely damaged by the lesion.

Yet, TN reported that he was able to perform the imagery task. This suggests that LOC and FFA are not necessary for object and person imagery and that the previously reported activations of category selective areas during imagery (Ishai, Ungerleider, & Haxby, 2000; O'Craven & Kanwisher, 2000) may not be a necessary condition for imagery to occur. This notion is supported by reports of intact visual imagery in cases of (prosop)agnosia (Bartolomeo, Bachoud-Levi, & Denes, 1997; Behrmann, Moscovitch, & Winocur, 1994; De Renzi & di Pellegrino, 1998; Michelon & Biederman, 2003). However, considering the exploratory nature of the present study, we did not provide detailed instructions to TN about color, size, texture, identity or physical appearance of the to be imagined stimuli. The present results therefore do not rule out that category selective areas may be involved in processing more specific aspects of imagery, as has been suggested for faces (Barton & Cherkasova, 2003). For instance, the FFA may be particularly involved in imagery of facial shape, but not facial features or face identity, which may be processed by other areas such as the temporal pole. Furthermore, while the lack of behavioral tests of visual imagery (e.g., Bartolomeo et al., 1998; Behrmann et al., 1994) is an important limitation and introspective evidence cannot indisputably prove the occurrence of visual imagery, the patient's self-reports are reassuring, particularly in combination with the imaging results.

4.2. Neural correlates of imagery

In line with the subjective report (see 4.1), the neural results provide evidence for imagery in a cortically blind patient. The data show that a bilateral fronto-parietal network was activated during visual imagery of an angry person as well during

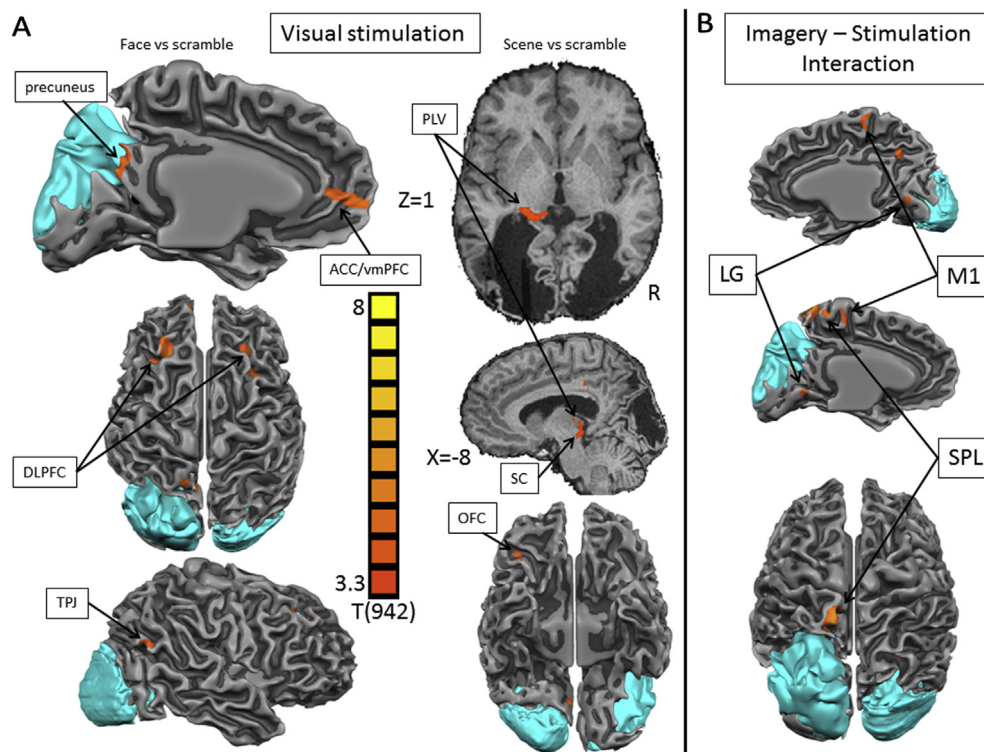


Fig. 4 – Statistical activation maps during the visual stimulation with faces or scenes compared to the scrambled images irrespective of the mental imagery task. The lesion is displayed in cyan. Talairach coordinates are reported. Statistical color coding is presented in the center. ACC/vmPFC = anterior cingulate cortex/ventromedial prefrontal cortex; PLV = pulvinar; DLPFC = dorsolateral prefrontal cortex; SC = superior colliculus; TPJ = tempo-parietal junction; OFC = orbitofrontal cortex. **B)** Statistical activation maps for the interaction between the mental imagery task and the visual stimulation (angry person imagery/angry face stimulation-angry person imagery/scrambled face stimulation) – [(angry person imagery/scene stimulation-angry person imagery/scrambled scene stimulation) + (tree imagery/angry face stimulation – tree imagery/scrambled face stimulation)]. The lesion is displayed in cyan. Statistical color coding is presented on the bottom right. M1 = primary motor cortex; LG = lingual gyrus; SPL = superior parietal lobule.

visual imagery of a tree, both compared to imagery of total darkness. This network has been associated with visuo-spatial imagery in normal subjects (Formisano et al., 2002) and it was also partly activated in the control subjects, albeit to a lesser extent. While visuo-spatial imagery may dissociate from visual imagery (Farah, Hammond, Levine, & Calvanio, 1988), in the latter, fronto-parietal activity is typically accompanied by temporal activity (Mechelli, Price, Friston, & Ishai, 2004), this seems not to be the case here.

In addition, we find activation in a fronto-parietal network specific for angry person imagery. The activations show that visual imagery of a person activates similar brain regions as when normal subjects with intact V1 imagine a person, as evidenced by the results in the control subjects as well as by previous studies (Blanke, Ionta, Fornari, Mohr, & Maeder, 2010; Bonda, Petrides, Frey, & Evans, 1995; Zacks, Rypma, Gabrieli, Tversky, & Glover, 1999; Zacks, Ollinger, Sheridan, & Tversky, 2002). These activations include premotor cortex (PMC), medial parietal cortex, early extrastriate visual cortex and caudate nucleus. Moreover, the control subjects also show activation in premotor, medial parietal and early extrastriate visual cortex, as well as in the cerebellum, which was also activated in TN. Hence there is a striking overlap between TN's activation on the one hand, and the activation in the control

subjects as well as in previously reported results on the other hand. The results from the control subjects in the present study primarily serve comparison purposes and do not allow generalizing to the normal population regarding emotion imagery. Nevertheless, there is substantial overlap in the activation observed in the control subjects and TN, which supports the report of TN that he was able to perform visual imagery.

This indicates that visual imagery activity is entirely feasible and specific for the target of the imagery task, consistent with an earlier behavioral study on another patient with bilateral V1 lesion (Zago et al., 2010). Moreover, cortical blindness and loss of V1 does not seem to abolish visual imagery processing that takes place in different and V1-independent brain networks. We also observed activation in extrastriate visual cortex (i.e., the lingual gyrus). This latter finding strongly suggests that the imagery task evokes the analogical representation of visual images. Previous studies have shown that the superior frontal gyrus (SFG) is active in mental imagery tasks and reflects working memory engagement during the task (for a review see Cabeza & Nyberg, 2000). In our results we see more extensive SFG activity for angry person than for tree imagery conditions.

In addition, imagining an angry person or a tree requires a different level of detail. For an angry person, one could first

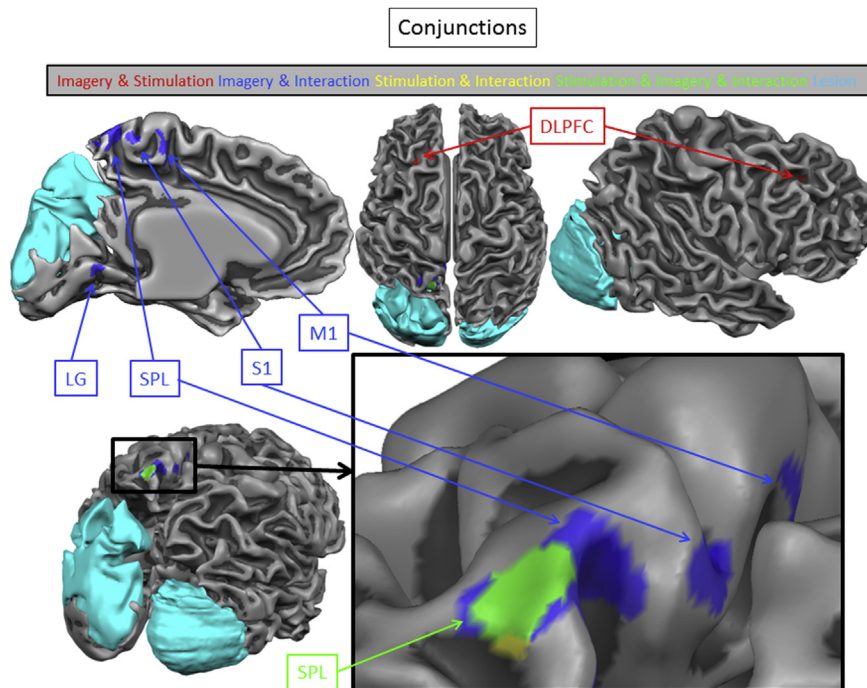


Fig. 5 – Conjunction results of mental imagery, visual stimulation and their interaction. DLPFC = dorsolateral prefrontal cortex; LG = lingual gyrus; SPL = superior parietal lobule; S1 = primary somatosensory cortex; M1 = primary motor cortex.

Table 2 – Results of conjunction analyses. XYZ refer to Talairach coordinates. t = t -value of peak voxel. N = number of voxels BA = Brodmann area;; SFG = superior Frontal Gyrus; PFC = prefrontal cortex; PMC = premotor cortex; MFG = middle frontal gyrus; preCG = precentral gyrus; postCG = postcentral gyrus; IPL = inferior parietal lobule; MTG = middle temporal gyrus; STS = superior temporal sulcus; TP = temporal pole; LG = lingual gyrus; SFS = superior frontal sulcus; ACC = anterior cingulate cortex; OFC = orbitofrontal cortex; SMG = supramarginal gyrus; AG = angular gyrus; PLV-SC-LGN = pulvinar-superior colliculus-lateral geniculate nucleus; SPL = superior parietal lobule.

Conjunction	X	Y	Z	t	p	N	BA
Angry person imagery – Angry face stimulation – Interaction							
Parietal							
SPL L	-13	-53	66	3.661	.0002	171	5
Angry person imagery – Angry face stimulation							
Frontal							
SFS L	-25	28	39	4.216	.00002	180	8
Parietal							
SPL L	-13	-53	66	3.661	.0002	171	5
Angry person imagery – Interaction							
Frontal							
preCG L	-7	-26	60	4.467	.000009	173	4
R	2	-26	60	4.332	.00001	425	4
Parietal							
SPL L	-10	-47	63	4.482	.000008	917	5
postCG L/R	-1	-44	63	3.904	.0001	336	3
Angry face stimulation – Interaction							
Parietal							
SPL L	-14	-53	69	3.867	.0001	206	5

imagine the person, then zoom in on the face and imagine the angry expression, imagine angry movements, while a tree can just be imagined once from the distance. It has been reported that these different levels of detail during imagining are associated with differential activation patterns in SMA/SFG, SPL and occipital cortex in normal subjects (Klein, Paradis, Poline, Kosslyn, & Le Bihan, 2000; Kosslyn, Thompson, Wraga, & Alpert, 2001). The present results are in line with this notion and are compatible with normal imagery mechanism in TN.

Two negative results are worth mentioning. First, one might expect amygdala activation during imagery of an angry person. Second, we did not find activity in the typical category-specific visual areas known from studies using neutral body or face images. Body imagery might have induced activation in the EBA, and synergy between body imagery combined with face stimulation might trigger activity in face specific areas like the occipital face area (OFA) or FFA. Large portions of these category-specific areas fall within the lesion but occipito-temporal network activations are still observed, though outside the lesioned areas and not in the category defined activations. One might take this as an indication that TN was imagining an abstract emotion rather than an actual angry person. Nevertheless, going against this interpretation and in favor of his dedicated imagery task performance, we did observe that person imagery activates the STS and also the temporal pole, two areas involved in social and person perception. Taken together, there are several indications that support the hypothesis that the activation in the imagery conditions reflect visual imagery, rather than emotional imagery. First, TN reported that he based his imagery on personal experiences, i.e., he claimed that he imagined specific autobiographical events concerning a tree

and angry person encounter. Second, the conjunction analysis between angry person versus total darkness imagery and tree versus total darkness imagery shows extensive activation in a fronto-parietal network that has also been reported in normal subjects performing visual imagery (Formisano et al., 2002). Third, the substantial overlap between TN and the control subjects in the activation during visual imagery. Finally, the ROI-analysis results show that the EBA, OFC, STS, SPL and amygdala are active during (unconscious) social perception (Van den Stock, Tamietto, Zhan, et al., 2014), but also during social imagery. Although these findings on their own do not directly prove imagery of visual details, their combination is strongly suggestive for a “visual” nature of the imagery. Furthermore complementary evidence is provided by the observed interaction between imagining a person and visual stimulation of a face discussed later.

4.3. Visual perception

The next set of findings relates to activations triggered by visual stimulation of either a face or a scene across all imagery conditions. Facial expressions activate regions that have also been associated with unconscious or covert face and facial expression perception in normal subjects. These include ventral medio-frontal areas (Liu et al., 2013), PMC (Balconi & Bortolotti, 2013), precuneus (Pantazatos, Talati, Pavlidis, & Hirsch, 2012), SMG (Pantazatos et al., 2012) and cerebellum (Van den Stock, Vandenbulcke, Zhu, Hadjikhani, & de Gelder, 2012). Remarkably, category-specific face processing areas along the ventral stream, such as the FFA or the OFA, were not activated in this contrast. This negative finding is consistent with a previous study on TN where non-conscious categorization of different stimuli was investigated behaviorally and with fMRI (Van den Stock, Tamietto, Zhan, et al., 2014). Behaviorally, TN was unable to categorize neutral faces above chance and the present detailed anatomical and functional analysis shows that nearly the complete FFA falls within the lesions and explain why they do not display any response to visual stimulation. The scenes versus scrambled scenes contrast shows OFC, postcentral gyrus, precuneus, SMG and AG. It has been proposed that the OFC is part of a top-down object recognition network and that its activation to low spatial frequency stimuli precedes activation in the ventral stream (Bar et al., 2006). Possibly, the OFC activation we observe here is triggered by subcortical input from magnocellular pathways, as it has been reported that subcortical structures like the SC and PLV are particularly sensitive to LSF stimulus properties (Vuilleumier, Armony, Driver, & Dolan, 2003) and are directly connected to OFC (Tamietto, Pullens, de Gelder, Weiskrantz, & Goebel, 2012). The activation in SC and PLV we observed here for the same contrast supports this hypothesis.

4.4. Influence of imagery on visual perception

The results from the interaction analysis provide evidence for the power of imagery to boost (non-conscious) visual perception. Although we controlled for effects of imagery and stimulation separately, we notice a substantial additive neural activation when socio-emotional imagery and socio-emotional stimulation are combined. Of particular interest is

also the finding that the interaction between angry person imagery and angry face visual stimulation yielded strong activation in the primary motor cortex (precentral gyrus), in the SPL and precuneus, and in extrastriate cortex. This pattern is in line with the notion that seeing, or in this case imagining angry body expressions prepares the brain to launch adaptive action (de Gelder, Snyder, Greve, Gerard, & Hadjikhani, 2004). Another interesting aspect relates to the conjunction results between the socio-emotional imagery/socio-emotional stimulation interactions. Noteworthy, more than half of the cortical activation during this imagery–stimulation interaction was also seen during imagery alone. This may reflect a clear potentiation of bottom-up processing by a top-down mechanism.

The left SPL is active for all three contrasts (angry person imagery, angry face visual stimulation, and their interaction). This suggests that SPL may constitute a core structure in affective processing during imaging as well as non-conscious visual perception, possibly reflecting sentience and feeling rather than cognitive emotional states (Damasio, 1999).

At the methodological level our results illustrate that mental imagery is a powerful tool for investigating residual visual abilities. In fact, bilateral V1 destruction poses unique challenges for vision research, as many of the mainstream tools, such as eye tracking calibration, retinotopic mapping or visual perimetry, are very difficult to use because of failure to control for eye-gaze and fixation. The methodology of comparing the intact and the damaged field in the same subject is also not possible, as well as the request to perform cognitive tasks based on imagery of visual stimuli previously presented in the intact field. Combining real visual presentations of unseen stimuli with mental imagery actually provides us with a novel and indirect testing method, which, compared to direct guessing procedures, is less subject to response bias and considered to be more sensitive (Savazzi & Marzi, 2002). Second, the study of mental imagery, providing visual imagery is still possible after V1 destruction, offers a unique chance to understand the neural basis of top-down influences over residual visual functions. In fact, cortical damage allows us to observe visual processing stripped of any interaction with actual conscious stimulus perception and of cognitive processes possibly involved in combining the two processes when the visual stimuli are consciously perceived.

Taken together, the present study provides three major findings. First, a dedicated mental imagery task is still possible for a fully cortically blind person and triggers activations specific for the imagined target. Second, residual and non-conscious visual abilities implemented in V1-independent pathways are still sufficient to activate areas not related to object category like face or body, but to person attributes. Finally, imagery and residual visual perception interact to boost activation in brain areas related to encoding the semantic dimension of the stimuli.

Acknowledgments

We are particularly grateful to TN for his cooperative participation in the study. The authors declare no competing financial interests. J.V.d.S. is a post-doctoral researcher supported

by FWO-Vlaanderen (1.5.072.13N). B.d.G. was partly funded by the project TANGO. The project TANGO acknowledges the financial support of the Future and Emerging Technologies (FET) program within the Seventh Framework Program for Research of the European Commission, under FET-Open grant number: 249858. B.d.G. also received funding from the European Research Council under the European Union's Seventh Framework Program (FP7/2007-2013)/ERC grant agreement number 295673. A.P. is supported by the Swiss National Science Foundation (grant no. 320030-144187). M.T. is supported by a "Vidi" grant from the Netherlands Organisation for Scientific Research (NWO) (grant 452-11-015), and partly by a FIRB – Futuro in Ricerca 2012 – grant from the Italian Ministry of Education University and Research (MIUR) (grant RBFR12F0BD) and by "GIRS" grant from the Regione Piemonte (bando Scienze Umane e Sociali 2008 – L.R.n.4./2006). The funding sources had no role in study design; in the collection, analysis and interpretation of data; in the writing of the report; and in the decision to submit the article for publication.

REFERENCES

- Bain, A. (1855). *The senses and the intellect*. New York: Appleton and Company.
- Balconi, M., & Bortolotti, A. (2013). Conscious and unconscious face recognition is improved by high-frequency rTMS on premotor cortex. *Consciousness and Cognition*, 22(3), 771–778. <http://dx.doi.org/10.1016/j.concog.2013.04.013>.
- Bar, M., Kassam, K. S., Ghuman, A. S., Boshyan, J., Schmid, A. M., Dale, A. M., et al. (2006). Top-down facilitation of visual recognition. *Proceedings of the National Academy of Sciences of the United States of America*, 103(2), 449–454.
- Bartolomeo, P., Bachoud-Levi, A. C., De Gelder, B., Denes, G., Dalla Barba, G., Brugieres, P., et al. (1998). Multiple-domain dissociation between impaired visual perception and preserved mental imagery in a patient with bilateral extrastriate lesions. *Neuropsychologia*, 36(3), 239–249.
- Bartolomeo, P., Bachoud-Levi, A. C., & Denes, G. (1997). Preserved imagery for colours in a patient with cerebral achromatopsia. *Cortex*, 33(2), 369–378.
- Bartolomeo, P., Bourgeois, A., Bourlon, C., & Migliaccio, R. (2013). Visual and motor mental imagery after brain damage. In S. Lacey, & R. Lawson (Eds.), *Multisensory Imagery* (pp. 249–269). New York: Springer.
- Barton, J. J., & Cherkasova, M. (2003). Face imagery and its relation to perception and covert recognition in prosopagnosia. *Neurology*, 61(2), 220–225.
- Behrmann, M., Moscovitch, M., & Winocur, G. (1994). Intact visual imagery and impaired visual perception in a patient with visual agnosia. *Journal of Experimental Psychology: Human Perception and Performance*, 20(5), 1068–1087.
- Blanke, O., Ionta, S., Fornari, E., Mohr, C., & Maeder, P. (2010). Mental imagery for full and upper human bodies: common right hemisphere activations and distinct extrastriate activations. *Brain Topography*, 23(3), 321–332. <http://dx.doi.org/10.1007/s10548-010-0138-x>.
- Bonda, E., Petrides, M., Frey, S., & Evans, A. (1995). Neural correlates of mental transformations of the body-in-space. *Proceedings of the National Academy of Sciences of the United States of America*, 92(24), 11180–11184.
- Bridge, H., Harrold, S., Holmes, E. A., Stokes, M., & Kennard, C. (2012). Vivid visual mental imagery in the absence of the primary visual cortex. *Journal of Neurology*, 259(6), 1062–1070. <http://dx.doi.org/10.1007/s00415-011-6299-z>.
- Bridge, H., Hicks, S. L., Xie, J., Okell, T. W., Mannan, S., Alexander, I., et al. (2010). Visual activation of extra-striate cortex in the absence of V1 activation. *Neuropsychologia*, 48(14), 4148–4154. <http://dx.doi.org/10.1016/j.neuropsychologia.2010.10.022>.
- Buetti, S., Tamietto, M., Hervais-Adelman, A., Kerzel, D., de Gelder, B., & Pegna, A. J. (2013). Dissociation between goal-directed and discrete response localization in a patient with bilateral cortical blindness. *Journal of Cognitive Neuroscience*, 25(10), 1769–1775. doi: 10.1162/jocn_a_00404.
- Burra, N., Hervais-Adelman, A., Kerzel, D., Tamietto, M., de Gelder, B., & Pegna, A. J. (2013). Amygdala Activation for Eye Contact Despite Complete Cortical Blindness. *Journal of Neuroscience*, 33(25), 10483–10489. <http://dx.doi.org/10.1523/JNEUROSCI.3994-12.2013>.
- Cabeza, R., & Nyberg, L. (2000). Imaging cognition II: an empirical review of 275 PET and fMRI studies. *Journal of Cognitive Neuroscience*, 12(1), 1–47.
- Damasio, A. R. (1999). *The feeling of what happens*. New York: Harcourt Brace.
- de Gelder, B., Snyder, J., Greve, D., Gerard, G., & Hadjikhani, N. (2004). Fear fosters flight: a mechanism for fear contagion when perceiving emotion expressed by a whole body. *Proceedings of the National Academy of Sciences of the United States of America*, 101(47), 16701–16706.
- de Gelder, B., Tamietto, M., van Boxtel, G., Goebel, R., Sahraie, A., van den Stock, J., et al. (2008). Intact navigation skills after bilateral loss of striate cortex. *Current Biology*, 18(24), R1128–1129. doi: S0960-9822(08)01433-4 [pii] 10.1016/j.cub.2008.11.002.
- De Renzi, E., & di Pellegrino, G. (1998). Prosopagnosia and alexia without object agnosia. *Cortex*, 34(3), 403–415.
- Downing, P. E., Jiang, Y., Shuman, M., & Kanwisher, N. (2001). A cortical area selective for visual processing of the human body. *Science*, 293(5539), 2470–2473. doi: 10.1126/science.1063414 293/5539/2470 [pii].
- Dulin, D., Cavezian, C., Serriere, C., Bachoud-Levi, A. C., Bartolomeo, P., & Chokron, S. (2011). Colour, face, and visuospatial imagery abilities in low-vision individuals with visual field deficits. *Quarterly Journal of Experimental Psychology Hove*, 64(10), 1955–1970. <http://dx.doi.org/10.1080/17470218.2011.608852>.
- Farah, M. J., Hammond, K. M., Levine, D. N., & Calvanio, R. (1988). Visual and spatial mental imagery: dissociable systems of representation. *Cognitive Psychology*, 20(4), 439–462.
- Forman, S. D., Cohen, J. D., Fitzgerald, M., Eddy, W. F., Mintun, M. A., & Noll, D. C. (1995). Improved assessment of significant activation in functional magnetic resonance imaging (fMRI): use of a cluster-size threshold. *Magnetic Resonance in Medicine*, 33(5), 636–647.
- Formisano, E., Linden, D. E., Di Salle, F., Trojano, L., Esposito, F., Sack, A. T., et al. (2002). Tracking the mind's image in the brain I: time-resolved fMRI during visuospatial mental imagery. *Neuron*, 35(1), 185–194.
- Frost, M. A., & Goebel, R. (2012). Measuring structural-functional correspondence: spatial variability of specialised brain regions after macro-anatomical alignment. *Neuroimage*, 59(2), 1369–1381. <http://dx.doi.org/10.1016/j.neuroimage.2011.08.035>.
- Guaita, A., Malnati, M., Vaccaro, R., Pezzati, R., Marcionetti, J., Vitali, S. F., et al. (2009). Impaired facial emotion recognition and preserved reactivity to facial expressions in people with severe dementia. *Archives of Gerontology and Geriatrics*, 49(Suppl 1), 135–146. <http://dx.doi.org/10.1016/j.archger.2009.09.023>.
- Haxby, J. V., & Gobbini, M. I. (2011). Distributed Neural Systems for Face Perception. In A. J. Calder, G. Rhodes, & M. Johnson (Eds.), *The Oxford Handbook of Face Perception* (pp. 93–110). New York: Oxford University Press.

- Ishai, A., Ungerleider, L. G., & Haxby, J. V. (2000). Distributed neural systems for the generation of visual images. *Neuron*, 28(3), 979–990.
- James, W. (1890). Imagination. In W. James (Ed.), *The Principles of Psychology, II* (pp. 30–55). New York: Holt.
- Klein, I., Paradis, A. L., Poline, J. B., Kosslyn, S. M., & Le Bihan, D. (2000). Transient activity in the human calcarine cortex during visual-mental imagery: an event-related fMRI study. *Journal of Cognitive Neuroscience*, 12(Suppl 2), 15–23. <http://dx.doi.org/10.1162/089892900564037>.
- Kosslyn, S. M., Alpert, N. M., Thompson, W. L., Maljkovic, V., Weise, S. B., Chabris, C. F., et al. (1993). Visual mental imagery activates topographically organized visual cortex: PET investigations. *Journal of Cognitive Neuroscience*, 5(3), 263–287.
- Kosslyn, S. M., Thompson, W. L., Wraga, M., & Alpert, N. M. (2001). Imagining rotation by endogenous versus exogenous forces: distinct neural mechanisms. *Neuroreport*, 12(11), 2519–2525.
- Le Bihan, D., Turner, R., Zeffiro, T. A., Cuenod, C. A., Jezzard, P., & Bonnerot, V. (1993). Activation of human primary visual cortex during visual recall: a magnetic resonance imaging study. *Proceedings of the National Academy of Sciences of the United States of America*, 90(24), 11802–11805.
- Liu, J., Wang, M., Shi, X., Feng, L., Li, L., Thacker, J. M., et al. (2013). Neural Correlates of Covert Face Processing: fMRI Evidence from a Prosopagnosic Patient. *Cerebral Cortex*. <http://dx.doi.org/10.1093/cercor/bht059>.
- Lundqvist, D., Flykt, A., & Öhman, A. (1998). *The Karolinska Directed Emotional Faces – KDEF*. Stockholm: Karolinska Institutet.
- Mechelli, A., Price, C. J., Friston, K. J., & Ishai, A. (2004). Where bottom-up meets top-down: neuronal interactions during perception and imagery. *Cerebral Cortex*, 14(11), 1256–1265. <http://dx.doi.org/10.1093/cercor/bhh087>.
- Metcalfe, K., Langdon, R., & Coltheart, M. (2010). The role of personal biases in the explanation of confabulation. *Cognitive Neuropsychiatry*, 15(1), 64–94. <http://dx.doi.org/10.1080/13546800902767703>.
- Michelon, P., & Biederman, I. (2003). Less impairment in face imagery than face perception in early prosopagnosia. *Neuropsychologia*, 41(4), 421–441.
- Mousikou, P., Coltheart, M., Finkbeiner, M., & Saunders, S. (2010). Can the dual-route cascaded computational model of reading offer a valid account of the masked onset priming effect? *Quarterly Journal of Experimental Psychology (Hove)*, 63(5), 984–1003. <http://dx.doi.org/10.1080/17470210903156586>.
- O'Craven, K. M., & Kanwisher, N. (2000). Mental imagery of faces and places activates corresponding stimulus-specific brain regions. *Journal of Cognitive Neuroscience*, 12(6), 1013–1023.
- Pantazatos, S. P., Talati, A., Pavlidis, P., & Hirsch, J. (2012). Cortical functional connectivity decodes subconscious, task-irrelevant threat-related emotion processing. *Neuroimage*, 61(4), 1355–1363. <http://dx.doi.org/10.1016/j.neuroimage.2012.03.051>.
- Pearson, D. G., Deeprose, C., Wallace-Hadrill, S. M., Burnett Heyes, S., & Holmes, E. A. (2013). Assessing mental imagery in clinical psychology: a review of imagery measures and a guiding framework. *Clinical Psychology Review*, 33(1), 1–23. <http://dx.doi.org/10.1016/j.cpr.2012.09.001>.
- Pegna, A. J., Khateb, A., Lazeyras, F., & Seghier, M. L. (2005). Discriminating emotional faces without primary visual cortices involves the right amygdala. *Nature Neuroscience*, 8(1), 24–25.
- Pegna, A. J., Landis, T., & Khateb, A. (2008). Electrophysiological evidence for early non-conscious processing of fearful facial expressions. *International Journal of Psychophysiology*, 70(2), 127–136. doi: S0167-8760(08)00776-9 [pii] 10.1016/j.ijpsycho.2008.08.007.
- Policardi, E., Perani, D., Zago, S., Grassi, F., Fazio, F., & Ladavas, E. (1996). Failure to evoke visual images in a case of long-lasting cortical blindness. *Neurocase*, 2, 371–394.
- Rode, G., Revol, P., Rossetti, Y., Boisson, D., & Bartolomeo, P. (2007). Looking while imagining: the influence of visual input on representational neglect. *Neurology*, 68(6), 432–437. <http://dx.doi.org/10.1212/01.wnl.0000252936.54063.b0>.
- Savazzi, S., & Marzi, C. A. (2002). Speeding up reaction time with invisible stimuli. *Current Biology*, 12(5), 403–407.
- Tamietto, M., & de Gelder, B. (2010). Neural bases of the non-conscious perception of emotional signals. *Nature Reviews Neuroscience*, 11(10), 697–709. doi: nrn2889 [pii] 10.1038/nrn2889.
- Tamietto, M., Pullens, P., de Gelder, B., Weiskrantz, L., & Goebel, R. (2012). Subcortical connections to human amygdala and changes following destruction of the visual cortex. *Current Biology*, 22(15), 1449–1455. <http://dx.doi.org/10.1016/j.cub.2012.06.006>.
- Van den Stock, J., Tamietto, M., Hervais-Adelman, A., Pegna, A. J., & de Gelder, B. (2014). Body Recognition in a Patient with Bilateral Primary Visual Cortex Lesions. *Biological Psychiatry*. <http://dx.doi.org/10.1016/j.biopsych.2013.06.023>. in press.
- Van den Stock, J., Tamietto, M., Sorger, B., Pichon, S., Grezes, J., & de Gelder, B. (2011). Cortico-subcortical visual, somatosensory, and motor activations for perceiving dynamic whole-body emotional expressions with and without striate cortex (V1). *Proceedings of the National Academy of Sciences of the United States of America*, 108(39), 16188–16193. <http://dx.doi.org/10.1073/pnas.1107214108>.
- Van den Stock, J., Tamietto, M., Zhan, M., Heinecke, A., Hervais-Adelman, A., Legrand, L. B., et al. (2014). Neural correlates of body and face perception following bilateral destruction of the primary visual cortices. *Frontiers in Behavioural Neuroscience*, 8, 30. <http://dx.doi.org/10.3389/fnbeh.2014.00030>.
- Van den Stock, J., Vandenbulcke, M., Sinke, C. B., & de Gelder, B. (2014). Affective scenes influence fear perception of individual body expressions. *Human Brain Mapping*, 35(2), 492–502. <http://dx.doi.org/10.1002/hbm.22195>.
- Van den Stock, J., Vandenbulcke, M., Sinke, C. B., Goebel, R., & de Gelder, B. (2014). How affective information from faces and scenes interacts in the brain. *Social Cognitive and Affective Neuroscience*, 9(10), 1481–1488. <http://dx.doi.org/10.1093/scan/nst138>.
- Van den Stock, J., Vandenbulcke, M., Zhu, Q., Hadjikhani, N., & de Gelder, B. (2012). Developmental prosopagnosia in a patient with hypoplasia of the vermis cerebelli. *Neurology*, 78(21), 1700–1702. <http://dx.doi.org/10.1212/WNL.0b013e3182575130>.
- Vuilleumier, P., Armony, J. L., Driver, J., & Dolan, R. J. (2003). Distinct spatial frequency sensitivities for processing faces and emotional expressions. *Nature Neuroscience*, 6(6), 624–631.
- Zacks, J., Rypma, B., Gabrieli, J. D., Tversky, B., & Glover, G. H. (1999). Imagined transformations of bodies: an fMRI investigation. *Neuropsychologia*, 37(9), 1029–1040.
- Zacks, J. M., Ollinger, J. M., Sheridan, M. A., & Tversky, B. (2002). A parametric study of mental spatial transformations of bodies. *Neuroimage*, 16(4), 857–872.
- Zago, S., Corti, S., Bersano, A., Baron, P., Conti, G., Ballabio, E., et al. (2010). A cortically blind patient with preserved visual imagery. *Cognitive Behavioral Neurology*, 23(1), 44–48. <http://dx.doi.org/10.1097/WNN.0b013e3181bf2e6e>.