

J. Van den Stock, PhD
M. Vandenbulcke, MD,
PhD
Q. Zhu, PhD
N. Hadjikhani, MD,
PhD
B. de Gelder, PhD

DEVELOPMENTAL PROSOPAGNOSIA IN A PATIENT WITH HYPOPLASIA OF THE VERMIS CEREBELLI

Individuals who have not acquired normal face recognition abilities but are otherwise cognitively intact have developmental prosopagnosia (DP). Although DP prevalence is estimated at around 2.5%, the neural underpinnings remain elusive and are presumably more heterogeneous than prosopagnosia acquired in adulthood. Here we report a patient exhibiting severe DP and hypoplasia of the vermis cerebelli.

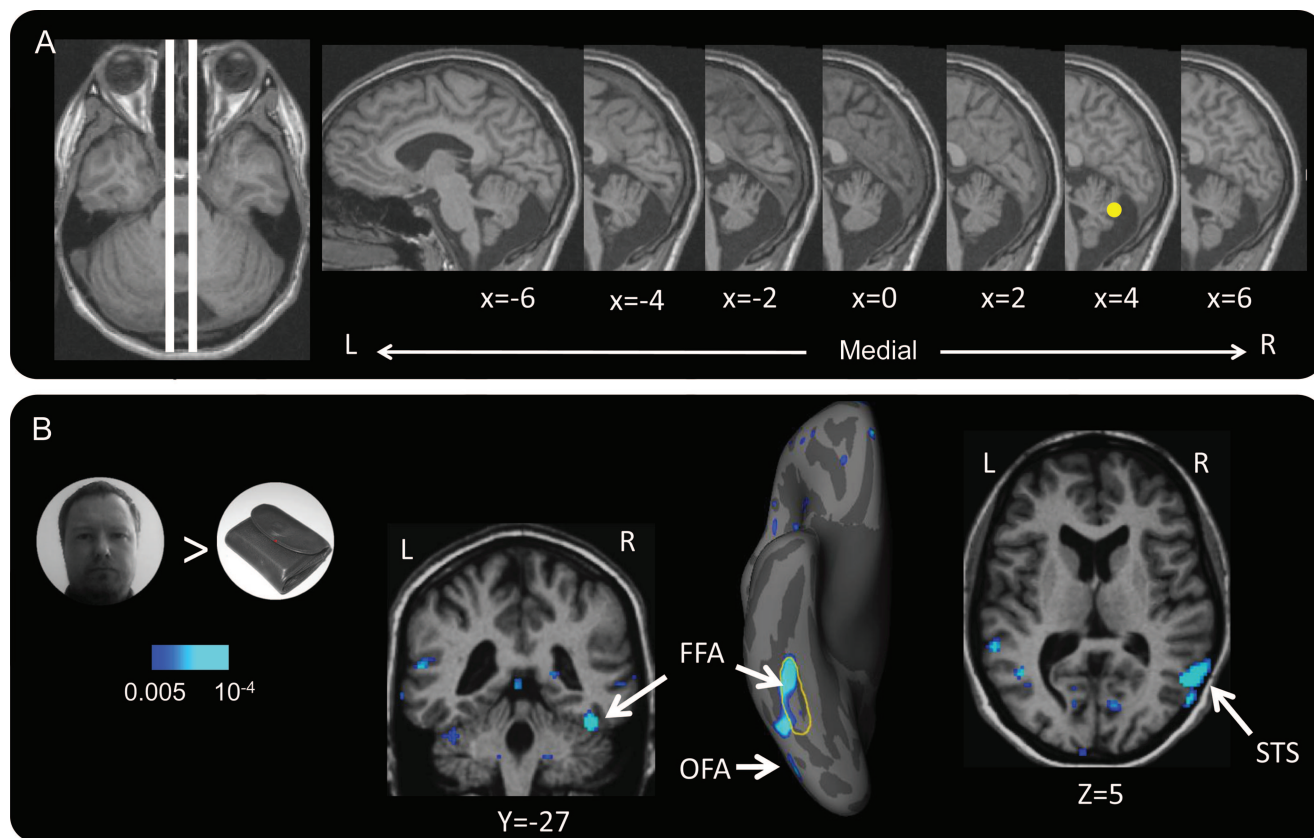
Case report. A 30-year-old right-handed female fitness instructor, with no neurologic or psychiatric history and holding a university degree in literary studies, consulted our department after observing remarkable similarities between her own daily experience of poor face-recognition abilities and descriptions provided in an article on prosopagnosia in the local newspaper. During intake, she reported lifelong difficulties in recognizing familiar faces. For instance, after individually coaching a regular fitness client during half an hour, she does not recognize him an hour later. The similar gym outfits and the absence of recognition cues beside the face exacerbate her problem. She does not watch movies, because she has problems telling apart the characters and does not recognize famous faces. She does not report difficulties recognizing familiar objects.

Behavioral testing. The patient performed within the normal range on a number of subtests of the Birmingham Object Recognition Battery (Match Length = 26/30; Size Match = 26/30; Orientation Match = 27/30; Position of Gap Match = 38/40; Minimal Feature View = 25/25; Foreshortened View = 25/25; Object Decision = 23/32), indicating that her low and midlevel visual perception and object recognition abilities are intact.

Her performance on a computerized Warrington Recognition Memory Test revealed impaired recognition memory for faces (accuracy = 36/50, Z score = -2.55 , $p < 0.005$; reaction time (RT) = 4,861 msec, Z score = -3.15 , $p < 0.001$) and her performance on the Benton Facial Recognition Test was at borderline level (40/54).

Imaging. MRI revealed hypoplasia of the vermis (figure) as the only abnormality. We localized her face-selective areas by means of fMRI.¹ Comparing faces with objects revealed activity in the well-known face regions: bilateral fusiform face area (FFA), right occipital face area (OFA), bilateral superior temporal sulcus (STS), and right amygdala. Her right FFA falls within the area activated in a group of 20 control subjects. Controls were scanned with the same protocol, but using a one-back task to activate short-term face and object memory processes. Two anatomically defined subdivisions of the vermis that are hypoplastic in the patient were more active during face memory processing than object memory processing in the control group (the vermis VI; Z score = 3.384; $p < 0.001$ and Crus II; Z score = 4.029; $p < 0.001$), indicating that the hypoplastic region is face-sensitive. She also took part in an fMRI study that we previously conducted with a DP group and normal controls.² The results of that study revealed decreased activation in the right FFA for perceiving neutral faces in the DP group (mean [SD] activation level = 4.8 [1.9]) compared to the control group (mean [SD] activation level = 8.5 [3.0]) ($p < 0.05$). Interestingly, her activation level (14.3) was among the highest of all subjects and significantly higher than the DPs ($Z = 4.76$; $p < 0.001$). We compared face-specific activity in the control and DP group in the cerebellar region missing in the patient and found no difference between the control and DP group ($p < 0.65$), suggesting that her face-recognition difficulties result from a different underlying mechanism than the DP group with intact vermis cerebelli.

The behavioral and neuroimaging findings point to a link between the face-recognition difficulties and hypoplasia of the vermis. Lesions³ and malformations⁴ of the cerebellum can lead to socioemotional and neuropsychiatric deficits like autistic-like symptoms, but also cognitive symptoms, including memory impairments. The deficit in prosopagnosia phenomenologically lies in face recognition memory, rather than in face perception: the clinical observation as well as the complaint of prosopagnosia patients is not that they have a deficit in perceiving faces, but they are impaired at recognizing familiar faces. It has been reported that face recognition



(A) Sagittal MRI slices of the patient's brain, showing hypoplasia of the vermis cerebelli. The yellow dot on slice X = 4 demarks the position of the local cerebellar maximum of reference 5 (indicating more activation for recognition memory of faces compared to spatial location). The vertical lines on the axial slice on the top left correspond to the position of the outer sagittal slices. (B) Stimulus examples from the functional face localizer experiment and the color coding corresponding to the statistical parametric maps (left). Face-selective activity from the patient projected on her brain showing right superior temporal sulcus (STS) (right) and right fusiform face area (FFA) (center). The bottom middle shows the FFA and occipital face area (OFA) of the patient projected on the averaged inflated right hemisphere of 20 control subjects. The yellow line demarks the contour of the face-selective activity in the control group. Coordinates refer to Montreal Neurological Institute space.

memory (measured with a 3-back task) is associated with activation of cerebellar midline structures.⁵ The cerebellar peak of activation in ref 5 borders on the missing area in the patient. Furthermore, a well-documented patient with acquired prosopagnosia has a lesioned vermis, although the prosopagnosia has hitherto been presumed to originate from occipito-temporal lesions.⁶ A study inducing a virtual lesion in the midline cerebellum by means of repetitive transcranial magnetic stimulation showed impaired processing of facial expressions.⁷

Our patient's imaging and clinical data support the hypothesis that hypoplasia of the cerebellar vermis and prosopagnosia are related and converge to describe a case of "cerebellar prosopagnosia." However, we grant that, when subclinical syndromic alterations and congenital abnormalities exist at the outset, functional brain reorganization may account for increased heterogeneity in clinical phenotypes.

From the Brain and Emotion Laboratory Leuven (BELL), Division of Psychiatry (J.V.d.S., M.V., B.d.G.), and Laboratory for Neuro- and

Psychophysiology (Q.Z.), Department of Neurosciences, KU Leuven, Leuven, Belgium; Cognitive and Affective Neuroscience Laboratory (J.V.d.S., B.d.G.), Tilburg University, Tilburg, the Netherlands; Brain Mind Institute (N.H.), Swiss Federal Institute of Technology, Lausanne, Switzerland; and Athinoula A. Martinos Centre for Biomedical Imaging (N.H., B.d.G.), Massachusetts General Hospital, Harvard Medical School, Charlestown.

Author contributions: Jan Van den Stock designed the study, analyzed and interpreted the data, and wrote the paper. Mathieu Vandenbulcke designed the study, interpreted the data, and wrote the paper. Qi Zhu analyzed and interpreted the data. Nouchine Hadjikhani designed the study and analyzed and interpreted the data. Beatrice de Gelder designed the study, interpreted the data, and wrote the paper.

J.V.d.S. and Q.Z. are postdoctoral researchers supported by FWO-Vlaanderen.

The authors report no disclosures relevant to the manuscript. **Go to Neurology.org for full disclosures.**

Received November 15, 2011. Accepted in final form January 17, 2012.

Correspondence & reprint requests to Dr. Van den Stock: jan.vandenstock@med.kuleuven.be

Copyright © 2012 by AAN Enterprises, Inc.

1. Hadjikhani N, de Gelder B. Neural basis of prosopagnosia: an fMRI study. *Hum Brain Mapp* 2002;16:176–182.

2. Van den Stock J, van de Riet WA, Righart R, de Gelder B. Neural correlates of perceiving emotional faces and bodies in developmental prosopagnosia: an event-related fMRI-study. *PLoS ONE* 2008;3:e3195.
3. Schmahmann JD, Sherman JC. The cerebellar cognitive affective syndrome. *Brain* 1998;121:561–579.
4. Tavano A, Grasso R, Gagliardi C, et al. Disorders of cognitive and affective development in cerebellar malformations. *Brain* 2007;130:2646–2660.
5. Courtney SM, Ungerleider LG, Keil K, Haxby JV. Object and spatial visual working memory activate separate neural systems in human cortex. *Cereb Cortex* 1996;6: 39–49.
6. Simon SR, Khateb A, Darque A, Lazeyras F, Mayer E, Pegna AJ. When the brain remembers, but the patient doesn't: converging fMRI and EEG evidence for covert recognition in a case of prosopagnosia. *Cortex* 2011;47: 825–838.
7. Schutter DJ, Enter D, Hoppenbrouwers SS. High-frequency repetitive transcranial magnetic stimulation to the cerebellum and implicit processing of happy facial expressions. *J Psychiatry Neurosci* 2009;34: 60–65.

AAN Publishes New Guidelines on Migraine Prevention

Research shows that many treatments can help prevent migraine in certain people, yet few people with migraine who are candidates for these preventive treatments actually use them, according to two new guidelines issued by the American Academy of Neurology. The guidelines were published in the April 24, 2012, issue of *Neurology*[®].

To read the guidelines and access PDF summaries for clinicians and patients, a slide presentation, and a clinical example, visit www.aan.com/go/practice/guidelines. For more information, contact Julie Cox at jcox@aan.com or (612) 928-6069.

AAN Webinars: Help for Your Practice, CME for Your Career

The American Academy of Neurology offers cost-effective Practice Management Webinars that can be attended live or through convenient recordings after the event. AAN members can benefit from *two free sessions* and save 25% on all regular webinars! Plus, registrants can earn 1.5 valuable CME credits for each webinar. For more information and to register, visit www.aan.com/view/pmweb today!

- Online Now **Decoding the 2012 Physician Fee Schedule: Changes that Impact Neurology (FREE to AAN members!)**
- Online Now **EHR Implementation: What You Need to Know from A-Z**
- Online Now **CPT Coding for Neurodiagnostic Procedures Made Easy**
- Online Now **Incentive Programs and Penalties: What Do They Mean for My Practice? (FREE to AAN members!)**
- Online Now **Ready, Set, Payment: Using Certified EHRs for Meaningful Use Payments**
- June 12 **The ABCs of Coding**
- July 17 **E/M: Minimize Mistakes, Maximize Reimbursement**
- September 18 **Thriving in the Face of an Audit**
- October 16 **ICD-10: Are You Prepared?**
- November 6 **Coding Accurately for Stroke and Critical Care**