



Multiple-domain dissociation between impaired visual perception and preserved mental imagery in a patient with bilateral extrastriate lesions

PAOLO BARTOLOMEO,*† ANNE-CATHERINE BACHOUD-LÉVI,†‡
BEATRICE DE GELDER,§¶ GIANFRANCO DENES,|| GIANFRANCO DALLA BARBA,*†
PIERRE BRUGIÈRES** and JEAN-DENIS DEGOS†

*INSERM Unit 324, Centre Paul Broca, 2ter rue d'Alésia, F-75014 Paris, France; †Neuroscience Department, Hôpital Henri-Mondor, Créteil, France; ‡LSCP, EHESS, CNRS, Paris, France; §Psychonomics Laboratory, Tilburg University, Tilburg, the Netherlands; ¶Laboratoire de Psychologie Expérimentale, Université Libre de Bruxelles, Brussels, Belgium; ||Dipartimento di Scienze Neurologiche e Psichiatriche, Università di Padova, Padua, Italy; **Neuroradiology Department, Hôpital Henri-Mondor, Créteil, France

(Received 7 May 1997; accepted 14 July 1997)

Abstract—A brain-damaged patient is described whose pattern of performance provides insight into both the functional mechanisms and the neural structures involved in visual mental imagery. The patient became severely agnostic, alexic, achromatopsic and prosopagnosic following bilateral brain lesions in the temporo-occipital cortex. However, her mental imagery for the same visual entities that she could not perceive was perfectly preserved. This clear-cut dissociation held across all the major domains of high-level vision: object recognition, reading, colour and face processing. Our findings, together with other reports on domain-specific dissociations and functional brain imaging studies, provide evidence to support the view that visual perception and visual mental imagery are subserved by independent functional mechanisms, which do not share the same cortical implementation. In particular, our results suggest that mental imagery abilities need not be mediated by early visual cortices. © 1998 Elsevier Science Ltd. All rights reserved

Key Words: agnosia; pure alexia; achromatopsia; prosopagnosia.

Introduction

Visual perception and visual mental imagery, the faculty whereby we can revisualize a visual item from memory, have often been regarded as cognitive functions subserved by common mechanisms. It has thus been hypothesized that visual perception and visual imagery share a number of mental operations [38], and rely upon common neural structures, including early visual cortices [15, 38]. In particular, a single visual buffer would be used “bottom-up”, to display visual percepts, and “top-down”, to display internally generated images. The proposed neural substrate for this buffer consists of some cortical visual areas organized retinotopically, that is, the striate and

extrastriate occipital areas [38]. Empirical support for these hypotheses comes from the report of brain-damaged patients showing an imagery deficit which parallels a perceptual impairment in the same cognitive domain (see [21] for review). However, this line of reasoning, although time-honoured and appealing in terms of elegance and parsimony, rests on the logic of association of impairments. This logic warrants the inference of a single mechanism underlying the co-occurrence of multiple deficits only until patients are described who show only one component deficit in isolation. Once a dissociation is documented, interpretations can no longer postulate a unitary mechanism [53]. For example, patients showing an association between perception and imagery deficits might have sustained brain lesions large enough to damage several functionally independent but anatomically contiguous cortical regions. Indeed, both reports of preserved perception with impaired imagery and of impaired perception with preserved imagery can

*Address for correspondence: INSERM Unit 324, Centre Paul Broca, 2ter rue d'Alésia, F-75014 Paris, France. Tel: +33 1 40 78 92 10; Fax: +33 1 45 80 72 93; e-mail: paolo@broca.inserm.fr.

be found in recent literature, thus making the case for a double dissociation for these deficits. Nevertheless, both types of dissociation have been claimed to accommodate the perception/imagery equivalence account; Farah [20] interpreted the isolated imagery deficits as coming from an impairment of the generation process, a mechanism specific to imagery by which memories are displayed on the visual buffer (though see [49] for the proposal of a separate image buffer); Kosslyn [38] argued that isolated perceptual deficits could come from an impairment of the sensory encoding system, prior to the visual buffer.

A further issue of interest in the imagery debate is the possible modularity of imagery abilities for different visual entities. The available descriptions of dissociations among preserved and impaired imagery abilities suggest domain-specific imagery for at least five types of visual entities, namely shapes of objects, colour of objects, faces, letters and spatial relationships [30]. Detailed knowledge of the patterns of co-occurrence of perceptual and imagery deficits in each of these domains is important in order to understand the cognitive and neural architecture of imagery abilities and their relationship with visual perception. For example, Farah [22] noted that patients with selective deficits in particular visual perceptual domains (e.g., colour or face processing) suffer from selective imagery deficits in the same domain. This finding supports the hypothesis that perception and imagery share a common representational machinery. A central achromatopsic patient thus said that an elephant would be green and a polar bear grey, but produced very good drawings of animals from memory [34], and a prosopagnosic patient could revisualize places, but not faces [55]. However, empirical evidence on these patterns of co-occurrence is scanty, because all the possible imagery domains were rarely, if at all, thoroughly investigated in the available case descriptions. For example, a dissociation between impaired perception and preserved imagery has been described in object agnosia [6, 7, 34, 37, 52], pure alexia [47], achromatopsia [54], prosopagnosia [32, 46, 60] and spatial hemineglect [4], but not all the domains of high-level vision were explored in each of these reports.

Here we describe a patient who, following bilateral lesions restricted to the extrastriate visual areas, was severely impaired in perceiving objects, letters, colours and in recognizing familiar faces. However, she was able to imagine vividly the same visual entities that she could not recognize, thus showing a dissociation holding across all these domains, which constitute the major components of high-level vision [25]. We describe her difficulties in each of the various domains and contrast them with her intact imagery capacity in each of these domains.

Methods

Case report

Madame D is a 74-year-old retired secretary who suffered a haematoma located across the left temporo-occipital sulcus in

May 1995, involving the middle and inferior occipital gyri and the inferior temporal gyrus (Brodmann areas 18, 19 and 37). Goldmann perimetry showed a right paracentral scotoma, which disappeared with IV/4 test. Her only neuropsychological deficit was a pure alexia. In December 1995, she sustained a second right-sided haematoma, almost symmetrical to the first. The lesion was centred on the middle occipital gyrus, just posteriorly to the temporo-occipital sulcus, involving areas 19 and 18 and the underlying white matter (Fig. 1).

After the occurrence of the second stroke, Mme D found herself unable to recognize familiar faces and common objects by sight, and complained of seeing the world in shades of grey. Visual fields were normal on confrontation test; Goldmann perimetry showed the persistence of the visual field defect (now apparent only with II test); however, the scotoma now extended to the left up to the foveal region (Fig. 2).

Visual evoked responses with black-and-white pattern were normal for latency and amplitude. At that time, the patient was unable to name any black-and-white realistic drawings. When asked to name real objects presented by the examiner, she was 13/35 correct on visual presentation, claiming that she was unable to recognize the other items. Tactile naming of the same objects was flawless. In February 1996, Mme D agreed to participate in experimental testing. At that time, she obtained a verbal IQ of 109 on the WAIS-R. She performed the screening test and the space perception test of the Visual Object and Space Perception Battery [58] correctly, but failed on all the object perception tests. On a test of line orientation judgement [8], she obtained a corrected score of 25, well within the normal limits. No signs of hemispatial neglect were present, either on visuo-spatial or on imaginal tasks [4]; in particular, when asked to describe known places from memory, Mme D provided accurate and symmetrical descriptions. Writing was preserved (Fig. 3(a)), and she was able to produce a plausible copy of a composite drawing (Fig. 3(b)).

However, she was severely impaired in perceiving colours, reading alphanumeric characters, and in recognizing by sight common objects and familiar faces, including her husband's. She was aware of and concerned about her perceptual impairments; she reported to try and identify objects by a slow, feature-by-feature approach†. When at home, she had learned to cope partly with her recognition problems; she could sometimes infer the identity of a familiar object by remembering its typical location; subsequently, she was able to "see" the object better by forming a visual image of it.

Procedure

Objects. Mme D was submitted to a battery designed to evaluate the visual perception of linear drawings (Protocole d'Evaluation des Gnosies Visuelles (PEGV); see [1]). This battery included tests of matching of geometrical patterns, identification of overlapping figures designing real objects and geometrical patterns, functional association of an object drawing with a target object drawing between two distractors (e.g., envelope with dice, stamp or stairs), and categorical association of object drawings (e.g., fork with watch, bicycle or knife). The latter two tests were also performed by orally presenting the stimuli. In addition, the patient was asked to match and subsequently name a series of 10 simple visual forms (linear drawings of polygons) to the corresponding items drawn on a paper sheet. The patient was asked to name 247 linear drawings from two standardized tests of oral confrontation picture naming

† For example, when shown the picture of a lion, she looked at it for a long time, saying: "There are four legs, then it should be an animal . . ."

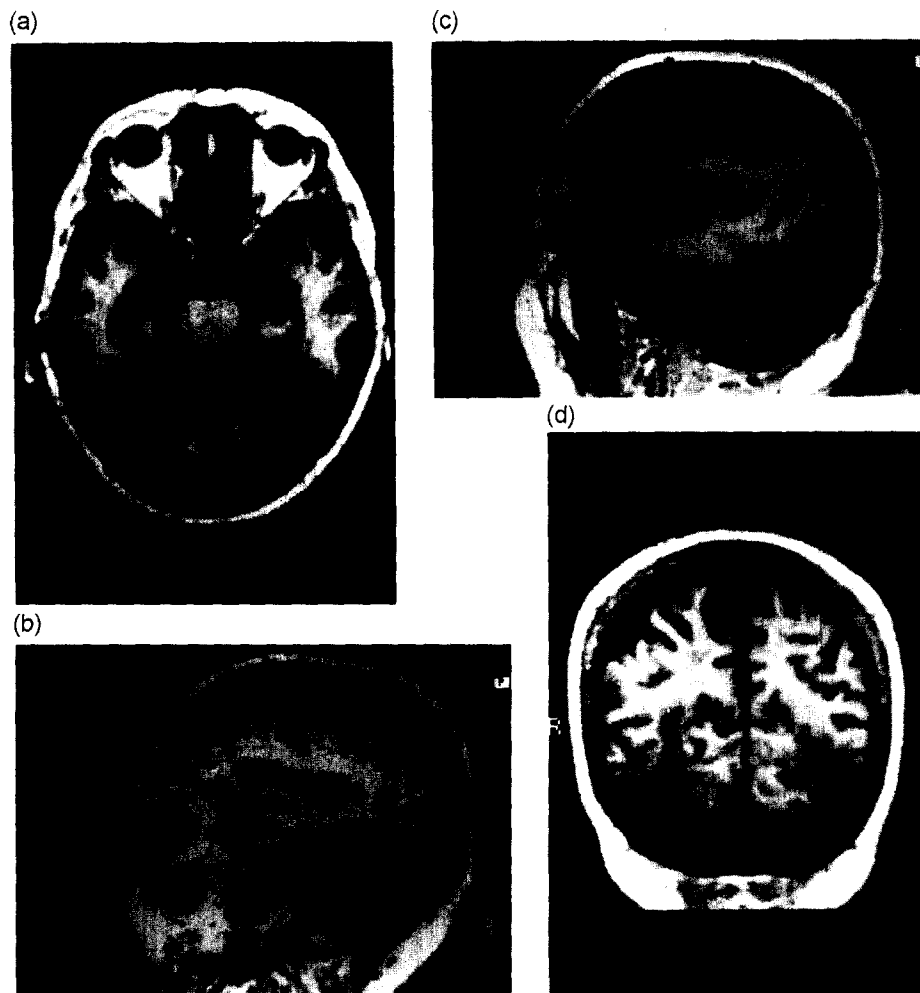


Fig. 1. T1-weighted MRI scan showing symmetric lesions in Brodmann areas 18 and 19 and in the underlying white matter. On the left side, the lesion extends anteriorly to the inferior temporal gyrus (BA 37). Transversal (a), sagittal (b, c) and coronal sections (d) are shown.

[17, 57]. Twenty linear drawings from one of these tests [17] were used for a matching task; they were scattered on the table in front of the patient, who was given a stimulus at a time and asked to match it to the corresponding stimulus on the table. Twenty different stimuli from the same test were used for a pointing task; they were also scattered on the table, and the patient was asked to point to the stimulus named by the examiner.

Imagery for objects and animals was tested using questionnaires requiring specific aspects of mental imagery [18, 39]. Examples of questions included: Do tractors have two large wheels in the back or in the front? Is a deer larger or smaller than a goat? Is a mug higher than it is wide or wider than it is high?

Reading. Two 100-word lists were presented for oral reading. Each list consisted of 20 words of four, five, six, seven and eight letters. The words were presented free-field, printed in lower case on a paper strip, for an unlimited time. Stimuli were matched for lexical frequency. Both lists were administered twice on different occasions. In addition, Mme D was asked to read individual lower-case letters and single-digit numbers presented on a paper strip.

Imagery for words and letters was tested by presenting auditorily the second word list to the patient, who was asked to state whether each word contained one or more letters with an

ascender (e.g., b, h), a descender (p, g), or neither (m, e) [59]. In a different testing session, the same question was asked for each letter of the alphabet. In addition, Mme D was required to decide from memory whether upper-case letters contained any curved lines [11] and to identify letters that she had constructed mentally following oral instructions [6]. An example from the latter task is: Take the letter M. Cut it in half vertically. Drop off the right side and turn the remaining part upside down (the answer is V). Imagery for numbers was tested by asking the patient to describe verbally single-digit numbers named by the examiner.

Colours. The Farnsworth dichotomous test [27] was administered twice on different occasions. Only responses crossing the centre of the isochromaticity diagram, i.e., couplings of very distant hues, were considered as wrong. The Ishihara test for colour-blindness [36] was administered allowing the patient to follow the targets' contour with her index finger, on account of her alexia. Matching, pointing and naming of colours were tested separately on different occasions. The patient was presented with a 16×20 cm board composed of 20 4×4 cm different colour patches, and asked to name the colours, or to point to colours pronounced by the examiner, or to match each colour with 20 separate 4×4 cm colour patches.

Colour imagery was tested by auditorily presenting names of objects to the patient, who had to produce either the appro-

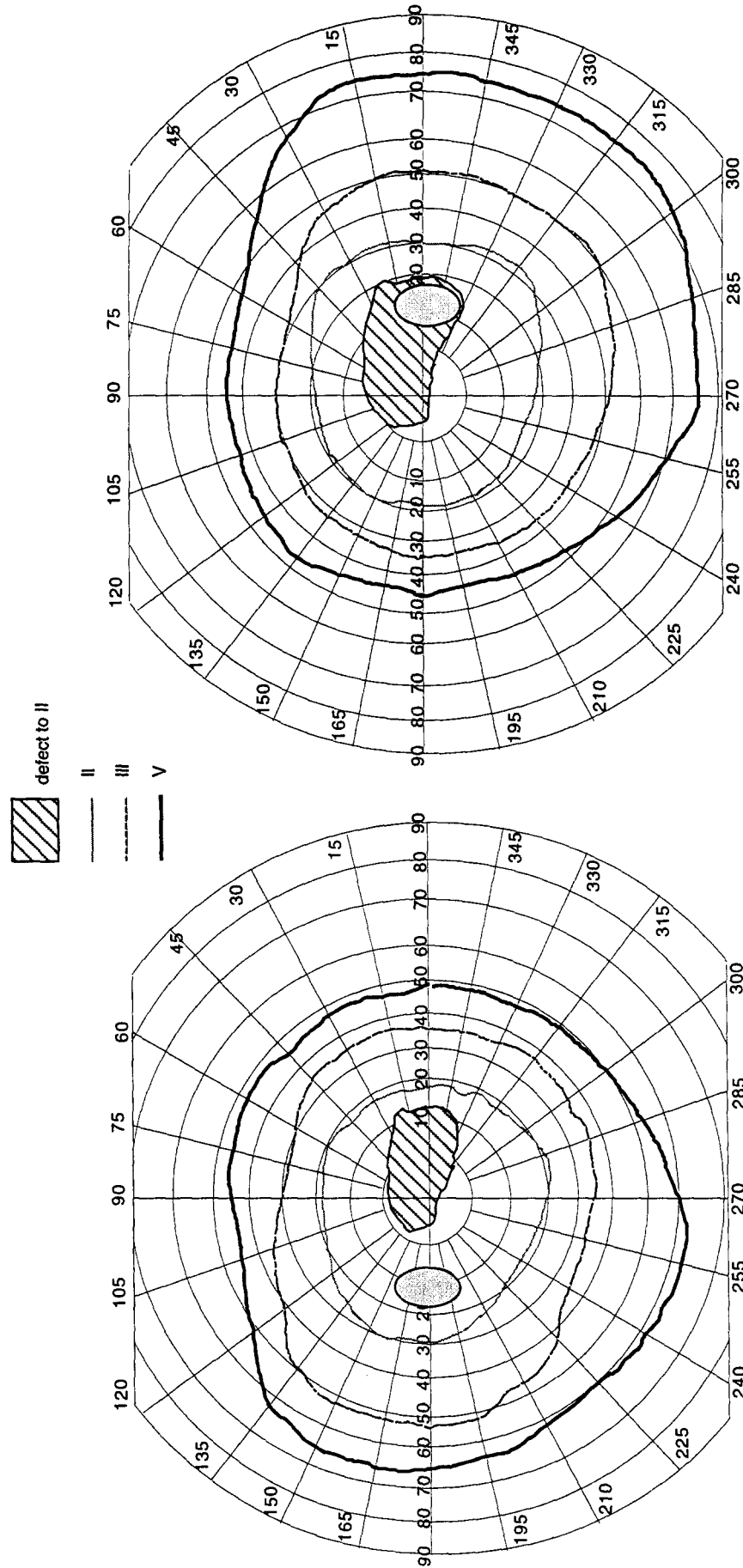


Fig. 2. Goldmann perimetry showing a relative central scotoma.

(a) Dans un chemin montagneux sablonneux
malais, et de tous les côtés au soleil exposé
six forts chevaux tiraient un coche




Fig. 3. Examples of Mme D's spontaneous writing (a), copy of a composite drawing (b), and drawing from memory of objects that she cannot identify on visual presentation (c).

priate colour, or to make hue discriminations between couples of objects (see [3] for a detailed description of tests).

Faces. Mme D was given tasks of face classification and facial decision [51]. She was required to classify photographs of unfamiliar faces by gender (10 men and 10 women), and by age (15 young, 15 aged). For the facial decision task, she was asked to discriminate between computer-drawn pictures of 10 faces and 10 non-faces. The non-faces were either missing a feature (nose, mouth, eyes), or their component features were scrambled. On this task, five control subjects (aged 35–81 years) performed 20/20 correct. In the task of detection of facial features, the patient was asked to match a facial feature (nose, mouth or eyes) to the corresponding item out of three distracters. The task consisted of three conditions in which targets were, respectively: isolated features ($n=9$), features in the context of a face ($n=9$), and features in a partial context (only hair, ears and chin; $n=9$). Recognition of celebrities was assessed by asking the patient to name 40 photographs of actors ($n=26$), or politicians ($n=14$), a task in which controls performed 39.2/40 correct. The task was administered twice on different occasions. Covert recognition of faces was assessed by a matching task, a face–name learning task, and a name–face interference task. In these tasks, covert recognition would lead, respectively, to superior performance on matching familiar faces, to faster relearning of familiar pairs, and to interference in deciding the professional category for celebrities' spoken names.

Imagery tests were designed using the same familiar faces used in the recognition task. Questions were asked about hair colour, length of hair, shape of mouth, length of nose, overall shape of the face (round, oval, etc.), or about the form of details of famous faces (e.g., “were a cast made of the lips of Marilyn Monroe, whose lips would it fit better, Brigitte Bardot's or Audrey Hepburn's?”). Odd-one out similarity judgements were asked about triads of familiar figures. Triads were constructed for the overall form and for particular aspects of the face (shape of the mouth, protrusion of the eyes, length of the nose) [60].

Results

Mme D's performance on perceptual and imagery tasks is summarized in Table 1.

She performed correctly the geometric pattern matching task of the PEGV (8/10 correct, cutoff <8), but failed on the overlapping figures task (13/30, cutoff <30) and on the association tasks (functional: 6/10, cutoff <9 ; categorical 3/10, cutoff <9). She showed no problem in the latter two tasks with oral presentation (both tasks, 10/10 correct). Mme D was severely impaired when naming linear drawings. Examples of her responses on such tasks are elephant — “it's an animal, a dog” or hammer — “aeroplane”. Never did she give any signs of recognizing items that she could not name (e.g., by miming of use). Moving the stimulus did not improve her performance. She was also impaired in matching and pointing to linear drawings, to the same degree as on confrontation naming [$\chi^2(2)=1.76$, P N.S.]. However, when asked to match and subsequently name simple visual shapes (polygons), she was faultless. Mme D produced plausible drawings when requested to draw from memory items that she could not identify (Fig. 3(c)). However, she did not recognize her drawings on subsequent testing sessions. She performed perfectly on the object imagery tests, thus revealing an intact ability to

imagine objects. Her only three non-responses concerned items that she claimed not to have known (star of David, tic-tac-toe game, beagle).

Mme D was severely alexic. She read words in a slow and laborious fashion, on a letter-by-letter basis, producing several errors. She also found it difficult to identify letters and numbers presented in isolation. Nevertheless, she could accurately visualize alphanumeric characters from memory. She stated rapidly and unhesitatingly whether lower-case letters or words named by the examiner had an ascender or a descender. She was equally good in deciding from memory whether upper-case letters contained any curved lines and when identifying letters that she had constructed mentally following oral instructions, a remarkably difficult task. Imagined numbers were also described correctly; for example, Mme D described from memory the number 6 (which she could not recognize in reading tasks) as “a half circle open toward the right, making a loop at its bottom”.

The same pattern of dissociation between severely impaired perception and intact mental imagery was present in the colour domain. Mme D was severely achromatopsic, though performing somehow better with saturated colours such as red. In spite of her achromatopsia, she was able to imagine colours vividly. She immediately retrieved from memory the colour of objects named by the examiner, even when colours could not be recalled using a verbal association strategy (e.g., interior part of a radish). She performed subtle hue discriminations between imagined colours; for example, she could state from memory that the green of bay leaves is darker than the green of French beans†.

Mme D was profoundly impaired in both overt and covert recognition of familiar faces, but had intact ability to consult the configural as well as the componential aspects of faces in mental imagery. She recognized the face of Mitterrand only once out of 40 photographs of celebrities presented twice on separate occasions, and performed at chance level on tasks requiring to classify by gender or by age photographs of unfamiliar people. Nevertheless, Mme D's performance was flawless when questioned about the shape of the mouth or the length of the nose of a particular face. On these tasks, Mme D's responses were identical to those given either by the total-ity or by the majority of controls.

Discussion

We presented the case of a patient with bilateral, well-defined brain lesions in the extrastriate visual areas. Her performance on neuropsychological tests tapping the visual processing of object form and colour, of verbal material and of faces was severely and uniformly

† See [3] for detailed results and discussion of Mme D's perceptual and imagery abilities in the colour domain.

Table 1. Patient's performance (proportion correct) on perceptual and imagery tests for objects, letters, colours and faces

	Perception	Imagery
<i>Objects</i>		
Matching of geometric patterns [1]	8/10	
Overlapping figures [1]	13/30	
Functional matching, visual presentation [1]	6/10	
Functional matching, oral presentation [1]	10/10	
Categorical association, visual presentation [1]	3/10	
Categorical association, oral presentation [1]	10/10	
Matching of simple visual shapes	10/10	
Naming of simple visual shapes	10/10	
Picture matching (stimuli from [17])	11/20	
Pointing to pictures (stimuli from [17])	7/20	
Oral confrontation picture naming [57]	94/167	
Oral confrontation picture naming [17]	39/80	
High-imagery sentences [18]		16/18
Animal size [39]		18/19
Object form [39]		24/24
<i>Letters</i>		
Word reading	156/400	
Letter reading	22/52	
Word imagery		100/100
Lower-case letter imagery [59]		26/26
Upper-case letter imagery [11]		26/26
Upper-case letter construction [6]		26/26
<i>Colours</i>		
Farnsworth D-15 [27]	17/32	
Ishihara plates [36]	6/36	
Colour matching [3]	6/20	
Colour pointing [3]	8/20	
Colour naming [3]	8/40	
Colour verbal memory [16]		20/20
Verbo-visuo-verbal test [5]		15/15
Mental hue comparison [3]		24/25
<i>Faces</i>		
Gender decision	12/20	
Age decision	11/30	
Facial decision [51]	14/20	
Facial features	5/27	
Recognition of celebrities	1/80	
Gender decision [51]	12/20	
Age decision [51]	11/30	
Overall similarity		15/45
Specific properties		14/15
Triads similarities [60]		30/30
Triads properties [60]		24/24

impaired. Nevertheless, she was able to revisualize vividly from memory items from all these perceptual domains, thus showing perfectly spared visual mental imagery abilities. As reviewed in the Introduction, dissociations between impaired perception and preserved imagery have already been described in object agnosia, pure alexia, achromatopsia and prosopagnosia. However, this is the first report of a similar dissociation holding across all these domains, which constitute the major components of high-level vision [25]. Our results bear implications for theories about the relationship between visual perception and visual mental imagery, for the notion of domain specificity in perceptual and imagery processes and for

current views about the neural basis of visual mental imagery.

Locus of impairment

The primary focus of the present study was to analyse the relationships between visual perception and visual imagery. Nevertheless, the association shown by our patient of multiple impairments in different visual perceptual domains, which are each likely to be subserved by a different functional module, requires some comments. An impairment of early visual processing (i.e., from the

retina to V1) could in principle account for the observed association, and would be consistent with the central scotoma†. However, a purely sensorial deficit seems to be excluded by the fact that Mme D is able to conduct a quasi-normal life when she is not confronted with complex visual items; she walks at home without bumping into objects, orients normally towards people and objects appearing in her visual fields, walks about in her neighbourhood, crossing streets and entering shops to buy items that she verbally indicates to the seller. It even happened that Mme D's friends doubted that her deficits were real, as it is often the case with patients suffering from selective neuropsychological impairments. The possibility of an early visual impairment also seems to be excluded by her good performance on a series of tasks, such as copying drawings, line orientation judgements, a neglect battery [4], the perceptual screening test and the spatial subtests of a visuospatial battery [58], and the geometric pattern-matching task of the PEGV [1], together with results of magnetic resonance imaging (MRI) and visual evoked potentials. Mme D's visual problems thus seem perceptual rather than sensorial in nature, and would perhaps best be classified as deficits of high-level visual processing.

Mme D's knowledge of the visual entities that she cannot perceive is preserved, as assessed by her perfect performance on tactile naming of objects and on imagery tasks for objects, letters, colours and faces. Our patient might suffer from a disrupted integration between the output of early sensory analysis and later stages of processing, and her functional locus of impairment is to be placed at some "intermediate" stage of processing (see [35]). In particular, our patient's pattern of performance does not conform to the classical dichotomy between aperceptive and associative agnosia [42]. This is not surprising, because Mme D's lesions are well defined and relatively restricted in size, and are thus likely to produce selective neuropsychological deficits. Mme D is relatively good at copying drawings (Fig. 3), and she is unimpaired in matching and naming simple visual shapes. As Humphreys and Riddoch's [34] patient, then, Mme D might suffer from a disrupted integration of simple visual features into perceptual wholes. Along with this argument goes the patient's report of attempts at identifying objects using a slow, feature-by-feature strategy. From the anatomical-functional point of view, this feature integration problem could reflect a deficit in the functional integration among striate and extrastriate visual areas necessary to produce a coherent percept of complex stimuli [61]; this deficit might in turn be caused by the critical location of lesions in our patient.

Implications for models of mental imagery

Our findings of a multiple-domain dissociation between perception and imagery, together with the location of our patient's lesions, place constraints on models of visual mental imagery. It is important to note that in our patient imagery abilities were not only relatively preserved compared with the perceptual deficit, but perfectly intact; besides her perfect accuracy, Mme D performed the imagery tasks in such a rapid and easy way to suggest that her imagery resources were entirely spared by the bilateral extrastriate lesions. We thus observed a dissociation between impaired performance in perceptual tests and normal performance in imagery tests. This type of dissociation, termed "classical" by Shallice [53], allows strong inferences about the normal mechanisms underlying the observed phenomena.

As was mentioned in the Introduction, current theories posit that mental imagery and perception share a visual buffer subserved by occipital visual areas [38], and that retrieval from memory occurs through the retroactivation of the same cortical areas that had processed the relevant information during perception [15]. Visual mental images would thus be produced by top-down activation of early visual cortices from more anterior areas. Such a mechanism could in principle explain our patient's pattern of performance, as early visual areas seemed spared by the lesions. However, the retroactivation account would have predicted at least a relative impairment of mental imagery in Mme D, given the massive disruption of the anterograde (bottom-up) flow of information and the anatomical contiguity between anterograde and reciprocal connections in the cerebral white matter. Contrary to this prediction, our patient performed at ceiling on all the mental imagery tasks. That early visual areas are not essential for revisualization from memory appears also from the descriptions of cortical-blind patients who were able to form visual images, from the classic Anton case [2] to recent reports [10, 31]; in those cortical-blind patients who do show mental imagery deficits, anatomical or metabolic damage extends from the early visual cortices to temporal and parietal areas [48]. Butter *et al.* [9] recently described eight patients with unilateral visual field defects who were worse at imagining dots on the side of their visual field defect than on the other side, a replication of analogous findings obtained by Farah *et al.* [26] in a single patient. Butter *et al.* concluded that "visual mental imagery relies on visual areas in the medial occipital lobe" ([9], p. 227). However, this conclusion is weakened by the following considerations. First, three patients out of eight did not undergo any neuroimaging studies; consequently, a lesion extending beyond the occipital cortex could not be excluded (such a lesion was indeed present in two of the remaining patients). Second, one hemianopic patient performed the imagery task normally. Third, even in the case of lesions anatomically restricted to the occipital cortex, functional damage may extend to other cortical areas, as in the patient described

† The scotoma can be explained by the possibility that the lesions affected the geniculocalcarine pathways; however, the possibility exists that an extrastriate lesion *per se* would be sufficient to create a visual field defect [33].

by Policardi *et al.* [48]. This possibility could not be excluded in the Butter *et al.* series, as no functional brain images were obtained. Moreover, in at least one patient in the series (M.K.), a functional impairment of the left temporal lobe was strongly suggested by the occurrence of an anomic deficit. Structural or functional damage to visual association areas might thus account for the imagery deficit observed by Butter *et al.* Also, a recent functional MRI study [14] showed activation of visual association areas in the absence of activation of the primary visual cortex during mental image generation.

The view that visual imagery relies on early visual areas is also inconsistent with current theories about the functional significance of these areas. For example, it has been argued that V1 is more likely to compute local interactions than to represent complex visual entities [45], and that neural activity in V1 does not directly enter awareness [13]; if so, it becomes even less plausible that the early visual areas subserved the conscious, high-level cognitive manipulations required to build up an internally generated image. These considerations, together with our present findings, challenge the claim that neural activity in areas 17 and 18 is essential for visual imagery (see [23, 40] for recent restatements). If our interpretation of Mme D's perceptual impairment as stemming from a disrupted integration between activity in the striate and extrastriate visual areas is correct, then this integration is clearly not essential for the retrieval of mental images, however complex they may be. The location of our patient's lesions at the border between the occipital and the temporal lobes would suggest that visual mental imagery is mediated by neural structures placed outside the occipital section of the occipito-temporal processing stream, in keeping with recent positron emission tomography (PET) data [28, 50], showing the activation of parietal and temporal association areas during visual imagery tasks. If so, a putative visual buffer shared by perception and imagery should be displaced either forward in the temporal lobe, or in the occipito-parietal stream.

That visual mental imagery requires the integrity of brain areas lying anteriorly to those lesioned in our patient is strongly suggested by the comparison between lesion locations in our patient and in patients with mental imagery impairment. Interestingly, when studies are considered in which information on lesion location is available, lesions anterior to the occipito-temporal sulcus with extensive temporal involvement are invariably present in patients with impaired revisualization of faces [19], colours [43] and objects [24]. Mental images of letters might have a different status, as they rely more heavily on subtle spatial constraints and might be used for the motor act of writing. An impairment of letter imagery might thus be expected, more than in pure alexic patients, in agraphic patients with parietal lesions. This seems indeed to be the case, as at least two left parietal patients have been described who showed signs of agraphia and loss of letter imagery [12, 29]. Also, evidence from lesion and PET studies indicates that spatial [41, 44] or motor

imagery [56] are likely to involve parietal and frontal areas. Future reports of imagery deficits in which different imagery abilities are carefully and thoroughly tested are needed further to specify these notions and to establish possible anatomo-functional correlations in selective imagery deficits for object shape, object colour or face processing.

Acknowledgements—This study was supported by the European Union grant ERBCHBGCT930344 to P.B. and by an INSERM grant to G.D. We thank M. Lafleur, C. Luzzatti, A. Petrov, A. Sirigu and L. Weiskrantz for comments on a previous version of the manuscript. V. Rosenthal kindly provided us with test material.

References

1. Agniel, A., Joannette, Y., Doyon, B. and Duchain, C., *Protocole Montréal-Toulouse d'Evaluation des Gnosies Visuelles*. L'Ortho-édition, Isbergues, 1992.
2. Anton, G., Über die Selbstwahrnehmungen der Herderkrankungen des Gehirns durch den Kranken bei Rindenblindheit. *Archiv für Psychiatrie und Nervenkrankheiten*, 1899, **32**, 86–127.
3. Bartolomeo, P., Bachoud-Lévi, A. C. and Denes, G., Preserved imagery for colours in a patient with cerebral achromatopsia. *Cortex*, 1997, **33**, 369–378.
4. Bartolomeo, P., D'Erme, P. and Gainotti, G., The relationship between visuospatial and representational neglect. *Neurology*, 1994, **44**, 1710–1714.
5. Beauvois, M. F. and Saillant, B., Optic aphasia for colours and colour agnosia: a distinction between visual and visuo-verbal impairments in the processing of colours. *Cognitive Neuropsychology*, 1985, **2**, 1–48.
6. Behrmann, M., Moscovitch, M. and Winocur, G., Intact visual imagery and impaired visual perception in a patient with visual agnosia. *Journal of Experimental Psychology: Human Perception and Performance*, 1994, **20**, 1068–1087.
7. Behrmann, M., Winocur, G. and Moscovitch, M., Dissociation between mental imagery and object recognition in a brain-damaged patient. *Nature*, 1992, **359**, 636–637.
8. Benton, A. L., Hamsher, K., Varney, N. R. and Spreen, O., *Contributions to Neuropsychological Assessment*. Oxford University Press, Oxford, 1983.
9. Butter, C. M., Kosslyn, S. M., Mijovic-Prelec, D. and Riffle, A., Field-specific deficits in visual imagery following hemianopia due to unilateral occipital infarcts. *Brain*, 1997, **120**, 217–228.
10. Chatterjee, A. and Southwood, M. H., Cortical blindness and visual imagery. *Neurology*, 1995, **45**, 2189–2195.
11. Coltheart, M., Hull, E. and Slater, D., Sex differences in imagery and reading. *Nature*, 1975, **253**, 434–440.
12. Cray, M. and Heilman, K., Letter imagery deficits in a case of pure apraxic agraphia. *Brain and Language*, 1988, **34**, 147–156.

13. Crick, F. and Koch, C., Are we aware of neural activity in primary visual cortex? *Nature*, 1995, **375**, 121–123.
14. D'Esposito, M., Detre, J. A., Aguirre, G. K., Stallcup, M., Alsop, D. C., Tippet, L. J. and Farah, M. J., Functional MRI study of mental image generation. *Neuropsychologia*, 1997, **35**, 725–730.
15. Damasio, A. Time-locked multiregional retro-activation: a system-level proposal for the neuronal substrates of recall and recognition. *Cognition*, 1989, **33**, 25–62.
16. De Renzi, E. and Spinnler, H., Impaired performance on color tasks in patients with hemispheric damage. *Cortex*, 1967, **3**, 194–217.
17. Deloche, G., Hannequin, D., Dordain, M., Perrier, D., Pichard, B., Quint, S., Metz-Lutz, M. C., Kremin, H. and Cardebat, D., Picture confrontation oral naming: performance differences between aphasics and normals. *Brain and Language*, 1996, **53**, 105–120.
18. Eddy, J. K. and Glass, A. L., Reading and listening to high and low imagery sentences. *Journal of Verbal Learning and Verbal Behavior*, 1981, **20**, 333–345.
19. Etcoff, N. L., Freeman, R. and Cave, K. L., Can we lose memories of faces? Content specificity and awareness in a prosopagnosic. *Journal of Cognitive Neuroscience*, 1991, **3**, 25–41.
20. Farah, M. J. The neurological basis of mental imagery: a componential analysis. *Cognition*, 1984, **18**, 245–272.
21. Farah, M. J. Is visual imagery really visual? Overlooked evidence from neuropsychology [Review]. *Psychological Review*, 1988, **95**, 307–317.
22. Farah, M. J., The neuropsychology of mental imagery. In *Handbook of Neuropsychology*, eds F. Boller and J. Grafman. Elsevier, Amsterdam, 1990, pp. 395–413.
23. Farah, M. J., The neural bases of mental imagery. In *The Cognitive Neurosciences*, ed. M. S. Gazzaniga. The MIT Press, Cambridge, MA, 1994, pp. 963–975.
24. Farah, M. J., Hammond, K., Levine, D. and Calvanio, R., Visual and spatial mental imagery: dissociable systems of representation. *Cognitive Psychology*, 1988, **20**, 439–462.
25. Farah, M. J. and Ratcliff, G. (editors) *The Neuropsychology of High-level Vision: Collected Tutorial Essays*. Lawrence Erlbaum Ass., Hillsdale, NJ, 1994.
26. Farah, M. J., Soso, M. J. and Dasheiff, R. M., Visual angle of the mind's eye before and after unilateral occipital lobectomy. *Journal of Experimental Psychology: Human Perception and Performance*, 1992, **18**, 241–246.
27. Farnsworth, D., *Farnsworth Dichotomous Test for Colour-blindness — Panel D-15*. The Psychological Corporation, New York, 1947.
28. Fletcher, P. C., Frith, C. D., Baker, S. C., Shallice, T., Frackowiak, R. S. J. and Dolan, R. J., The mind's eye — Precuneus activation in memory-related imagery. *Neuroimage*, 1995, **2**, 195–200.
29. Friedman, R. B. and Alexander, M. P., Written spelling apraxia. *Brain and Language*, 1989, **36**, 503–517.
30. Goldenberg, G. The neural basis of mental imagery. *Baillière's Clinical Neurology*, 1993, **2**, 265–286.
31. Goldenberg, G., Mullbacher, W. and Nowak, A., Imagery without perception — a case study of anosognosia for cortical blindness. *Neuropsychologia*, 1995, **33**, 1373–1382.
32. Hécaen, H., de Ajuriaguerra, J., Magis, C., Angeleagues, R. Le problème de l'agnosie des physionomies. *L'Encéphale*, 1952, **41**, 322–355.
33. Horton, J. C. and Hoyt, W. F., Quadrantic visual field defects: a hallmark of lesions in extrastriate (V2/V3) cortex. *Brain*, 1991, **114**, 1703–1718.
34. Humphreys, G. W. and Riddoch, M. J., *To See But Not To See: A Case Study of Visual Agnosia*. Lawrence Erlbaum Ass., London, 1987.
35. Humphreys, G. W., Riddoch, M. J., Donnelly, N., Freeman, T., Boucart, M. and Muller, H. M., Intermediate visual processing and visual agnosia. In *The Neuropsychology of High-Level Vision: Collected Tutorial Essays*, eds M. J. Farah and G. Ratcliff. Lawrence Erlbaum Ass., Hillsdale, NJ, 1994, pp. 63–101.
36. Ishihara, S., *Tests for Colour-blindness*. Kanehara Shup, Tokyo, 1974.
37. Jankowiak, J., Kinsbourne, M., Shalev, R. S. and Bachman, D. L., Preserved visual imagery and categorization in a case of associative visual agnosia. *Journal of Cognitive Neuroscience*, 1992, **4**, 119–131.
38. Kosslyn, S. M., *Image and Brain: The Resolution of the Imagery Debate*. The MIT Press, Cambridge, MA, 1994.
39. Kosslyn, S. M., Holtzman, J. D., Farah, M. J. and Gazzaniga, M. S., A computational analysis of mental image generation: evidence from functional dissociations in split-brain patients. *Journal of Experimental Psychology: General*, 1985, **114**, 311–341.
40. Kosslyn, S. M., Thompson, W. L., Kim, I. J. and Alpert, N. M., Topographical representations of mental images in primary visual cortex. *Nature*, 1995, **378**, 496–498.
41. Levine, D. N., Warach, J. and Farah, M., Two visual systems in mental imagery: Dissociation of “what” and “where” in imagery disorders due to bilateral posterior cerebral lesions. *Neurology*, 1985, **35**, 1010–1018.
42. Lissauer, H. Ein Fall von Seelenblindheit nebst einem Beitrage zur Theorie derselben. *Archiv für Psychiatrie und Nervenkrankheiten*, 1890, **21**, 222–270.
43. Luzzatti, C. and Davidoff, J., Impaired retrieval of object-colour knowledge with preserved colour naming. *Neuropsychologia*, 1994, **32**, 933–950.
44. Mellet, E., Tzourio, N., Crivello, F., Joliot, M., Denis, M. and Mazoyer, B., Functional anatomy of spatial mental imagery generated from verbal instructions. *The Journal of Neuroscience*, 1996, **16**, 6504–6512.
45. Nelson, M. E. and Bower, J. M., Brain maps and parallel computers. *Trends in Neurosciences*, 1990, **13**, 403–408.
46. Pallis, C. A. Impaired identification of faces and places with agnosia for colours — report of a case due to cerebral embolism. *Journal of Neurology, Neurosurgery and Psychiatry*, 1955, **18**, 218–224.
47. Perri, R., Bartolomeo, P. and Silveri, M. C., Letter

- dyslexia in a letter-by-letter reader. *Brain and Language*, 1996, **53**, 390–407.
48. Policardi, E., Perani, D., Zago, S., Grassi, F., Fazio, F. and Ladavas, E., Failure to evoke visual images in a case of long-lasting cortical blindness. *Neurocase*, 1996, **2**, 371–394.
 49. Riddoch, M. J. Loss of visual imagery: a generation deficit. *Cognitive Neuropsychology*, 1990, **7**, 249–273.
 50. Roland, P. E. and Gulyas, B., Visual imagery and visual representation. *Trends in Neurosciences*, 1994, **17**, 281–287.
 51. Schweich, M. and Bruyer, R., Heterogeneity of the cognitive manifestations of prosopagnosia: the study of a group of single cases. *Cognitive Neuropsychology*, 1993, **10**, 529–547.
 52. Servos, P. and Goodale, M. A., Preserved visual imagery in visual form agnosia. *Neuropsychologia*, 1995, **33**, 1383–1394.
 53. Shallice, T., *From Neuropsychology to Mental Structure*. Cambridge University Press, New York, 1988.
 54. Shuren, J. E., Brott, T. G., Schefft, B. K. and Houston, W., Preserved color imagery in an achromatopsic. *Neuropsychologia*, 1996, **34**, 485–489.
 55. Shuttleworth, E. C., Syring, V. and Allen, N., Further observations on the nature of prosopagnosia. *Brain and Cognition*, 1982, **1**, 307–322.
 56. Sirigu, A., Duhamel, J. R., Cohen, L., Pillon, B., Dubois, B. and Agid, Y., The mental representation of hand movements after parietal cortex damage. *Science*, 1996, **273**, 1556–1559.
 57. Snodgrass, J. G. and Vanderwart, M., A standardized set of 260 pictures: norms for name agreement, image agreement, familiarity and visual complexity. *Journal of Experimental Psychology: Human Learning and Memory*, 1980, **6**, 174–215.
 58. Warrington, E. K. and James, M., *The Visual Object and Space Perception Battery*. Thames Valley Test Company, Bury St Edmunds, 1991.
 59. Weber, R. J. and Castleman, J., The time it takes to imagine. *Perception and Psychophysics*, 1970, **8**, 165–168.
 60. Young, A. W., Humphreys, G. W., Riddoch, M. J., Hellawell, D. J., de Haan, E. H. F. Recognition impairments and face imagery. *Neuropsychologia*, 1994, **32**, 693–702.
 61. Zeki, S. and Shipp, S., The functional logic of cortical connections. *Nature*, 1988, **335**, 311–317.